Interventional Ultrasound

A Practical Guide and Atlas

Edited by
Christoph F. Dietrich
Dieter Nuernberg

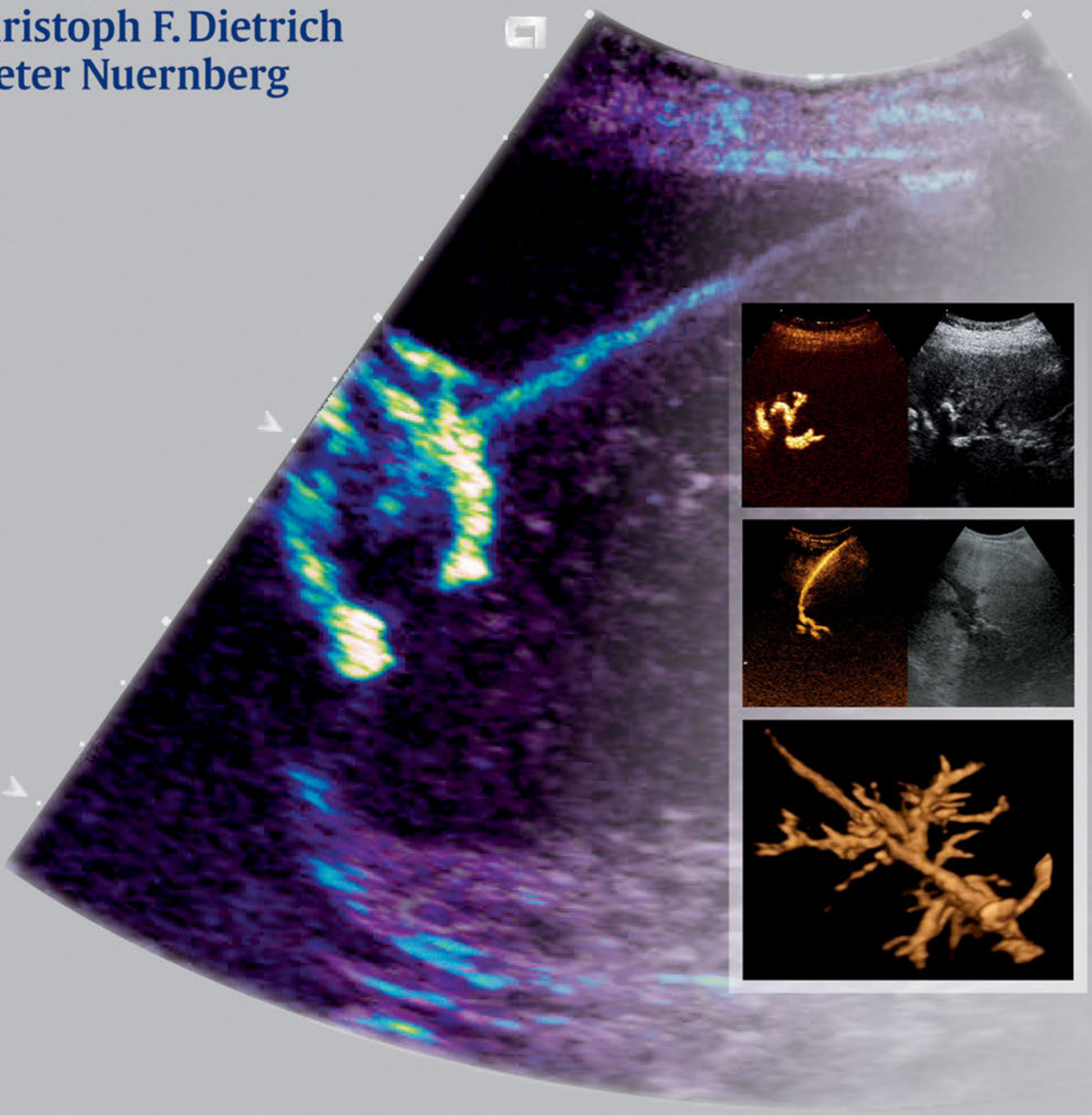

Thieme

Thieme

Interventional Ultrasound

A Practical Guide and Atlas

Christoph F. Dietrich, MD
Professor and Head Physician
Medical Clinic 2
Caritas Hospital Bad Mergentheim gGmbH
Bad Mergentheim, Germany

Dieter Nuernberg, MD
Professor and Head Physician
Medical Clinic B
Ruppiner Hospitals GmbH
Neuruppin, Germany

380 illustrations

Thieme
Stuttgart • New York • Delhi • Rio

Library of Congress Cataloging-in-Publication Data

Interventioneller Ultraschall. English.
Interventional ultrasound : a practical guide and atlas / [edited by] Christoph F. Dietrich, Dieter Nuernberg ; translator, Terry C. Telger ; illustrator, Helmut Holtermann.
p. ; cm.
Includes bibliographical references and index.
ISBN 978-3-13-170821-2 – ISBN 978-3-13-170831-1 (eISBN)
I. Dietrich, Christoph Frank, editor. II. Nuernberg, Dieter, editor. III. Title.
[DNLM: 1. Ultrasonography, Interventional. WN 208]
RC78.7.U4
616.07'543–dc23

2014028919

This book is an authorized translation of the German edition published and copyrighted 2011 by Georg Thieme Verlag, Stuttgart. Title of the German edition: Interventionelle Ultraschall: Lehrbuch und Atlas für die Interventionelle Songraphie

Translator: Terry C. Telger, Fort Worth, TX, USA

Illustrator: Helmut Holtermann, Dannenberg, Germany

MIX
Paper from responsible sources
FSC® C021256
FSC
www.fsc.org

© 2015 Georg Thieme Verlag KG

Thieme Publishers Stuttgart
Rüdigerstrasse 14, 70469 Stuttgart, Germany
+49 [0]711 8931 421, customerservice@thieme.de

Thieme Publishers New York
333 Seventh Avenue, New York, NY 10001, USA
1-800-782-3488, customerservice@thieme.com

Thieme Publishers Delhi
A-12, Second Floor, Sector-2, Noida-201301
Uttar Pradesh, India
+91 120 45 566 00, customerservice@thieme.in

Thieme Publishers Rio,
Thieme Publicações Ltda.
Argentina Building, 16th Floor, Ala A,
228 Praia do Botafogo Rio de Janeiro
22250-040 Brazil
+55 21 3736-3631

Cover design: Thieme Publishing Group
Typesetting by Thomson Digital, India

Printed in Germany by Aprinta Druck, Wemding

ISBN 978-3-13-170821-2

Also available as an e-book:
eISBN 978-3-13-170831-1

Important note: Medicine is an ever-changing science undergoing continual development. Research and clinical experience are continually expanding our knowledge, in particular our knowledge of proper treatment and drug therapy. Insofar as this book mentions any dosage or application, readers may rest assured that the authors, editors, and publishers have made every effort to ensure that such references are in accordance with **the state of knowledge at the time of production of the book.**

Nevertheless, this does not involve, imply, or express any guarantee or responsibility on the part of the publishers in respect to any dosage instructions and forms of applications stated in the book. **Every user is requested to examine carefully** the manufacturers' leaflets accompanying each drug and to check, if necessary in consultation with a physician or specialist, whether the dosage schedules mentioned therein or the contraindications stated by the manufacturers differ from the statements made in the present book. Such examination is particularly important with drugs that are either rarely used or have been newly released on the market. Every dosage schedule or every form of application used is entirely at the user's own risk and responsibility. The authors and publishers request every user to report to the publishers any discrepancies or inaccuracies noticed. If errors in this work are found after publication, errata will be posted at www.thieme.com on the product description page.

Some of the product names, patents, and registered designs referred to in this book are in fact registered trademarks or proprietary names even though specific reference to this fact is not always made in the text. Therefore, the appearance of a name without designation as proprietary is not to be construed as a representation by the publisher that it is in the public domain.

This book, including all parts thereof, is legally protected by copyright. Any use, exploitation, or commercialization outside the narrow limits set by copyright legislation without the publisher's consent is illegal and liable to prosecution. This applies in particular to photostat reproduction, copying, mimeographing preparation of microfilms, and electronic data processing and storage.

Contents

Foreword xviii

Preface xix

Acknowledgments xx

Contributors xxi

Abbreviations xxiii

General Aspects of Interventional Ultrasound

1 Interventional Ultrasound: Introduction and Historical Background 2
H. Lutz

1.1 The Vienna Congress 2

1.2 The Introduction of Ultrasound into Routine Clinical Use 3

1.2.1 The Evolution of Ultrasound Imaging Techniques 3
1.2.2 Technical Evolution of Ultrasound-Guided Biopsies 4
1.2.3 Clinical Application 7
1.2.4 Risks of Interventional Ultrasound 9

1.3 Later Developments: Ultrasound-Guided Therapeutic Interventional Procedures 10

1.4 Outlook 10

References 11

2 Interventional Materials and Equipment 13

2.1 General Considerations on Interventional Procedures 13
U. Gottschalk, C. F. Dietrich

2.1.1 Brief Historical Introduction 13
2.1.2 Biopsy Principles and Techniques 13
2.1.3 Needle Systems 15

2.2 Therapeutic Interventions 20

2.2.1 Introduction 20
2.2.2 Brief Historical Review 20
2.2.3 Patient Preparation 21
2.2.4 Access Routes 21
2.2.5 Indications and Contraindications 21
2.2.6 Complications 22
2.2.7 Needle Techniques 23
2.2.8 Special Needle Types 23
2.2.9 Trocar Technique 23
2.2.10 Seldinger Technique 24
2.2.11 Peel-Away Sheath 24
2.2.12 Anchor Systems, Suture Techniques 25
2.2.13 Guidewires 26
2.2.14 Dilators 27
2.2.15 Drainage Catheters 27
2.2.16 Other Drainage Systems 29
2.2.17 Accessories 29
References 31

3 Informed Consent 32
D. Nuernberg, A. Jung

3.1 What Should Be Disclosed? 32

3.1.1 Indication 32
3.1.2 Explaining the Procedure 32
3.1.3 Risks and Complications 32

3.2 Means of Disclosure 32

3.2.1 Consent Form 32
3.2.2 Informed Consent Discussion 32
3.2.3 Delegating Informed Consent 33

3.3 Documentation 33
3.4 Timing of the Consent Process 33
3.5 Special Situations 33
3.5.1 Implied Consent 33
3.5.2 Patients Lacking the Capacity to Consent 33
3.5.3 Minors. 33
3.5.4 Language Barriers 34
3.5.5 Waiving of Informed Consent 34
References 34

4 Medications, Equipment, and Setup Requirements 35
D. Nuernberg, A. Jung

4.1 Medications 35
4.1.1 Premedication 35
4.1.2 Analgesia. 35
4.1.3 Coagulation 36
4.1.4 Local Anesthesia 36
4.2 Equipment and Setup Requirements . . 37
4.2.1 Biopsy Equipment. 37
4.2.2 Interventional Materials. 37
4.2.3 Positioning, Preprocedure Examination, and Marking. 37
4.2.4 Monitoring During the Procedure. 37
4.2.5 Postprocedure Monitoring. 37
4.2.6 Facilities (Procedure Room). 37
4.2.7 Functional and Design Requirements. 38
4.2.8 Operational and Organizational Requirements. 38
References 38

5 Pathology and Cytology 40
A. Tannapfel, C. F. Dietrich

5.1 Pathology 40
5.2 Biopsies 40
5.2.1 Types of Biopsy Procedure 40
5.3 Histology or Cytology? 40
5.3.1 Sources of Error 41
5.4 Typing, Grading, and Staging 41
5.4.1 Classification (Typing). 41
5.4.2 Grading. 43
5.5 Specific Analysis 43
5.5.1 Lymph Nodes 43
5.5.2 Lymphomas 45
5.6 Hormone Growth Factor Receptor Analysis 47
References 48

6 Fine Needle Aspiration Cytology. 49
C. Jenssen, T. Beyer

6.1 Specimen Collection 49
6.1.1 Ultrasound-Guided Biopsy 49
6.1.2 Needle Movement and Aspiration 49
6.2 Specimen Preparation. 49
6.2.1 Fluid Aspirates. 49
6.2.2 Centrifuging Effusions 49
6.2.3 Aspirates from Solid Lesions 50
6.3 Fixation and Staining. 55
6.3.1 Basic Principles 55
6.3.2 Air Drying and Romanowsky Stains 55
6.3.3 Wet Fixation and Papanicolaou Staining . . 55
6.3.4 Ancillary Tests 56
6.4 Cytomorphologic Evaluation. 58
6.4.1 Rapid On-Site Evaluation 58
6.4.2 Final Cytologic Diagnosis 63
6.5 Conclusions 64
References 64

7 Infections and Diagnostic Microbiology ... 68
T. Glueck, H. J. Linde, C. F. Dietrich

7.1 General Principles of Microbiological Testing ... 68
7.1.1 Microbiological Specimens ... 68
7.1.2 Prerequisites for Microbiological Testing ... 68

7.2 Microbiological Techniques ... 69
7.2.1 Stains ... 69
7.2.2 Culture Techniques ... 71
7.2.3 Nucleic Acid Amplification Techniques ... 71
7.2.4 Serology ... 71
7.2.5 When Are Microbiological Test Results Available? ... 72
7.2.6 Limitations of Microbiological Methods ... 72
7.2.7 Specimen Receipt during Off-hours (Nights, Weekends, Holidays) ... 72

7.3 Specific Guidelines for Microbiological Testing and Differential Diagnosis by Organ Systems and Syndromes ... 73
7.3.1 Investigation of Enlarged Lymph Nodes ... 73
7.3.2 Microbiological Testing and Antimicrobial Therapy for Suspected Tuberculosis ... 76
7.3.3 Liver Mass Suspicious for an Abscess (Including Amebic Abscess) ... 77
References ... 81

8 Hygiene Management ... 82
H. Martiny, D. Nuernberg

8.1 General Hygienic Requirements ... 82
8.1.1 Personal Protective Equipment and Coverings ... 82
8.1.2 Disposable Probe Covers ... 83
8.1.3 Ultrasound Gel ... 83

8.2 Hand Antisepsis and Skin Preparation ... 83

8.3 Ultrasound Probe and Accessories ... 84
8.3.1 Decontamination of the Ultrasound Probe ... 84
8.3.2 Decontamination of Ultrasound Accessories ... 85
References ... 85

9 Contraindications, Complications, and Complication Management ... 86
C. Jenssen, C. F. Dietrich

9.1 Interventional Risk ... 86
9.1.1 Complication Rates and Mortality ... 86
9.1.2 Factors that Influence Interventional Risk ... 86

9.2 Frequent Complications and Their Risk Factors ... 86
9.2.1 Pain and Vasovagal Reactions ... 86
9.2.2 Bleeding Complications ... 87
9.2.3 Needle Tract Seeding ... 88
9.2.4 Specific Complications ... 89

9.3 Prevention of Complications ... 89
9.3.1 Risk Assessment and Patient Selection ... 89
9.3.2 Modification of Risk Factors ... 90
9.3.3 Risk Reduction Techniques ... 92
9.3.4 Local Anesthesia and Intravenous Sedation ... 92
9.3.5 Prevention of Infection ... 93
9.3.6 Optimal Approach and Alternatives ... 93

9.4 Contraindications ... 93
9.4.1 Coagulopathies ... 93
9.4.2 Procoagulant Therapy and Antiplatelet Drugs ... 94
9.4.3 “Risky” Lesions and Access Routes ... 94

9.5 Management of Complications ... 95
9.5.1 Postinterventional Care and Detection of Complications ... 95
9.5.2 Treatment of Complications ... 95

9.6 Specific Biopsy Sites ... 95
9.6.1 Liver Biopsy ... 95
9.6.2 Renal Biopsy ... 99
9.6.3 Pancreatic Biopsy ... 99
9.6.4 Splenic Biopsy ... 100

9.6.5 Biopsy of Gastrointestinal Hollow Organs and Mesenteric Masses . . . 100
9.6.6 Adrenal Biopsy . . . 100
9.6.7 Lungs, Pleura, and Mediastinum . . . 101

9.7 Specific Interventions . . . 101

9.7.1 EUS-FNA, EUS-TCB, EBUS-TBNA . . . 101
9.7.2 EUS-Guided Therapeutic Interventions . . . 101
9.7.3 Transrectal Prostatic Biopsy . . . 102
9.7.4 Ultrasound-Guided Drainage (of Cysts, Pseudocysts, Abscesses, Cholecystitis) . . . 102
9.7.5 Ultrasound-Guided PTCD and Cholecystotomy . . . 103
9.7.6 Ultrasound-guided Tumor Ablation Therapy . . . 103
References . . . 104

10 Assistance in Ultrasound Interventions . . . 109
U. Gottschalk, C. F. Dietrich

10.1 Basic Principles . . . 109

10.2 Duties of Assisting Personnel . . . 109

10.3 Diagnostic Ultrasound . . . 110

10.4 Diagnostic Interventions . . . 110

10.5 Therapeutic Interventions . . . 111

10.6 Sedation . . . 111

10.7 Drain Placement . . . 111

10.8 Endosonography . . . 113

References . . . 113

11 Sedation in Interventions . . . 114
U. Gottschalk, C. F. Dietrich

11.1 Introduction . . . 114

11.2 Medications . . . 114

11.3 Personnel Requirements . . . 114

11.4 Monitoring Requirements . . . 115

11.5 Postprocedure Care . . . 115

11.6 Complications . . . 115

11.7 Summary . . . 115

References . . . 115

Specific Ultrasound-Guided Procedures: Abdomen

12 Indications for Diagnostic Interventions in the Abdomen and Thorax (Liver, Pancreas, Spleen, Kidneys, Lung, Other Sites) . . . 120
H. Kinkel, D. Nuernberg

12.1 Liver . . . 120

12.1.1 Diffuse Liver Diseases . . . 120
12.1.2 Focal Liver Lesions . . . 121

12.2 Pancreas . . . 123

12.3 Spleen . . . 123

12.4 Kidneys . . . 124

12.5 Lung . . . 125

12.6 Adrenal Gland . . . 125

12.7 Lymph Nodes . . . 125

12.8 Other Lesions . . . 126

References . . . 126

13 Diagnostic and Therapeutic Paracentesis of Free Abdominal Fluid 128
D. Nuernberg

13.1 Peritoneal Cavity 128

13.2 Sites of Predilection for Intra-abdominal Fluid 128

13.3 Pathogenesis and Differential Diagnosis of Ascites 129

13.4 Specific Indications 129

13.4.1 Transudate 129
13.4.2 Exudate 129
13.4.3 Cirrhosis 130
13.4.4 Heart Failure 130
13.4.5 Hypoalbuminemia 130
13.4.6 Peritonitis 130
13.4.7 Peritoneal Carcinomatosis 130
13.4.8 Hemoperitoneum 130
13.4.9 Pancreatitis 131
13.4.10 Other Rare Abdominal Fluid Collections 131

13.5 Differentiating a Localized Fluid Collection from Ascites 133

13.6 Practical Issues: How and Where to Aspirate? 133

13.7 Diagnostic Paracentesis: Laboratory Tests 134

13.8 Indications for Therapeutic Paracentesis 134

13.8.1 Treatment of Ascites in Hepatic Cirrhosis: Paracentesis for Symptom Relief in Hepatic Cirrhosis (and Pancreatitis) 134
13.8.2 Palliative Paracentesis for Peritoneal Carcinomatosis 135
13.8.3 Cytostatic Therapy of Peritoneal Carcinomatosis (Intraperitoneal Chemotherapy) 135
13.8.4 Drainage (with Irrigation) for Bile Leakage (For Example in a Palliative Setting) 135

13.9 Materials 136

13.10 Contraindications, Complications, and Postprocedure Care 136

References 137

14 Fine Needle Aspiration Biopsy and Core Needle Biopsy 138
J.-C. Kaemmer, D. Nuernberg

14.1 Historical Background 138

14.2 Description of Biopsy Techniques 138

14.2.1 What Type of Needle Should Be Used? 138

14.3 Biopsy Technique for Specific Needle Types 141

14.3.1 Biopsy with the Chiba Needle 142
14.3.2 Cutting Biopsy with an Otto or Franseen Needle 142
14.3.3 Autovac and BioPince Biopsy Systems 142
14.3.4 Biomol Biopsy System 143
14.3.5 Trucut Needles 143

14.4 Summary 143

References 143

15 Abscess Drainage 144
C. F. Dietrich, A. Ignee, U. Gottschalk

15.1 Historical Considerations 144

15.2 Preliminary Remarks, Etiology 144

15.3 Selection of Imaging Modality 144

15.3.1 Ultrasound 144
15.3.2 Conventional Radiographic Drainage 146
15.3.3 Computed Tomography 146
15.3.4 Magnetic Resonance Imaging 146

15.4 Devices 146

15.4.1 Drainage Catheters 146

15.5 Indications 147

15.6 Contraindications 147

15.7 Patient Preparation 147

15.8 Treatment Options 148

15.8.1 General 148
15.8.2 Medical Treatment Options 148
15.8.3 Surgical Treatment Options 148

15.9 Technique of Percutaneous Abscess Drainage 148

15.9.1 Preparation. 148
15.9.2 Initial Needle Insertion. 149
15.9.3 Trocar Technique. 151
15.9.4 Irrigation. 154
15.9.5 Drain Removal 154
15.9.6 Specimen Processing. 154

15.10 Postprocedure Care 154

15.11 Specific Diseases 154

15.11.1 Pyogenic Liver Abscess 154
15.11.2 Abscesses in Appendicitis, Peridiverticulitis 155
15.11.3 Liver Abscess in Biliary Disease 155
15.11.4 Abscess in Pancreatitis 156
15.11.5 Liver Abscess in Amebiasis. 156
15.11.6 Protozoan Infections with Liver Involvement. 157
15.11.7 Septic (Pyogenic) Abscess with Associated Diseases (Sepsis, Coagulopathies, Ascites) 157
15.11.8 Infection of Necrotic Tumor Components. 158
15.11.9 Liver Abscess after Liver Transplantation 158

15.12 Complications 158

15.13 Irrigation 159

15.14 Sequelae 159

15.15 Ultrasound-Guided Gallbladder Drainage and Other Indications 159

References 160

16 Percutaneous Sclerotherapy of Cysts 163

C. F. Dietrich, B. Braden

16.1 Percutaneous Sclerotherapy of Liver Cysts 163

16.1.1 Epidemiology and Etiology 163
16.1.2 Symptoms. 163
16.1.3 Indications 163
16.1.4 Contraindications 163
16.1.5 Interventional Materials and Equipment. . 163
16.1.6 Sclerosing Agents 163
16.1.7 Treatment Options 163
16.1.8 Technique for Percutaneous Sclerotherapy of a Liver Cyst. 163

16.2 Sclerotherapy Technique 164

16.2.1 Follow-up Care 164
16.2.2 Prognosis 164

16.3 Percutaneous Sclerotherapy of Renal Cysts 164

16.3.1 Summary of the Literature. 164
16.3.2 Epidemiology, Differential Diagnosis, and Classification 165
16.3.3 Technique. 166
16.3.4 Sclerosing Agents 166

16.4 Alternative Procedures 167

16.5 Special Issues Relating to Splenic Cysts 167

16.6 Special Issues Relating to Pancreatic Cysts 167

References 167

17 Interventional Treatment of Echinococcosis. 168

C. F. Dietrich, M. Hocke

17.1 Echinococci: Types and Epidemiology. . 168

17.1.1 *Echinococcus granulosus*. 168
17.1.2 *Echinococcus multilocularis* 169

17.2 Clinical Manifestations 169

17.3 Diagnosis. 169

17.3.1 Three Main Diagnostic Criteria 169

17.3.2 Laboratory Parameters 169
17.3.3 Serologic and Molecular Biologic Tests . . . 169

17.4 Imaging Studies, Staging of Disease . . . 169

17.4.1 Historical Background 169
17.4.2 Morphologic and Functional Classification Systems 171
17.4.3 WHO Classification 171

17.5 Treatment 173

17.5.1 Surgical Treatment Options 174
17.5.2 Drug Treatment Options. 174
17.5.3 Local Ablative Procedures: PAIR 175
17.5.4 Endoscopic Retrograde Cholangiography 177
References 177

18 Local Ablative Procedures; Percutaneous Ethanol and Acetic Acid Injection 179

C. F. Dietrich, B. Braden, M. Hocke

18.1 Basic Considerations 179

18.1.1 What Tumors Are Suitable for Local Ablative Procedures?. 179
18.1.2 Radiofrequency Ablation or Percutaneous Ethanol Injection? 179
18.1.3 Ethanol or Acetic Acid Injection? 179
18.1.4 Single or Multiple Sessions? 179

18.2 Indications 179

18.2.1 Considerations on Hepatocellular Carcinoma 180

18.3 Contraindications 180

18.4 Practical Aspects 180

18.4.1 Materials and Equipment. 180
18.4.2 Preparations. 180
18.4.3 Technique. 180

18.5 Follow-up Care, Complications, and Prognosis 182

18.5.1 Follow-up Care 182
18.5.2 Complications 182
18.5.3 Monitoring of Treatment Response 182
18.5.4 Factors That Determine Prognosis 183

18.6 Summary. 183

References 183

19 Local Ablative Procedures for Liver Tumors, Radiofrequency Ablation 185

C. F. Dietrich, T. Albrecht, T. Bernatik, A. Ignee

19.1 Concepts (Curative, Palliative, Multimodal) 185

19.1.1 Hepatocellular Carcinoma 185
19.1.2 Colorectal Carcinoma 185

19.2 Selection of Imaging Modality (Ultrasound, CT, MRI) 186

19.3 Indications 186

19.3.1 Number of Tumors 186
19.3.2 Tumor Size 186
19.3.3 Tumor Location 186

19.4 Contraindications 187

19.5 Preparations. 187

19.5.1 Antibiotic Prophylaxis 187
19.5.2 Local Anesthesia, Sedation, Sedation/Analgesia, and General Anesthesia 187
19.5.3 Treatment Planning. 187

19.6 Materials 187

19.6.1 Standard Materials 187
19.6.2 Basic Principle 188
19.6.3 Monopolar versus Bipolar and Multipolar Systems. 188
19.6.4 Needle Applicators 189
19.6.5 Control and Temperature Measurement. 189
19.6.6 Flow Rate of Needle Perfusion. 189

19.7 Technique 189

19.7.1 Patient Positioning 189
19.7.2 (Local) Anesthesia 190
19.7.3 Probe Insertion 190
19.7.4 Techniques for Specific Systems 191

19.8 Assessing the Efficacy of Treatment ... 192

19.9 Complications and Aftercare ... 193

19.9.1 Complications ... 193

19.9.2 Postinterventional Care ... 196

19.9.3 Clinical Aftercare and Follow-up ... 196

References ... 196

20 Percutaneous Transhepatic Cholangiodrainage ... 198

C. F. Dietrich, B. Braden, X. W. Cui, A. Ignee

20.1 Basic Principles ... 198

20.2 Indications ... 198

20.2.1 Endoscopic Retrograde or Percutaneous Approach ... 199

20.2.2 Rendezvous Technique ... 199

20.3 Contraindications ... 199

20.4 Materials and Equipment ... 200

20.4.1 Description of Materials ... 200

20.5 Technique ... 201

20.5.1 Patient Positioning ... 202

20.5.2 Needle Insertion and Drainage ... 202

20.5.3 Procedure Time ... 207

20.6 Success Rate ... 207

20.6.1 Results with Plastic Endoprostheses ... 207

20.6.2 Results with Metal Endoprostheses ... 208

20.7 Complications ... 208

20.7.1 Incidence ... 208

20.7.2 Management of Complications ... 208

20.8 Aftercare ... 208

20.9 Use of Intracavitary Ultrasound Contrast Agents ... 209

20.10 Analysis of the Literature ... 210

20.10.1 Present Authors' Data ... 210

20.10.2 Comparison of Endoprostheses ... 210

References ... 212

21 Percutaneous Gastrostomy ... 215

A. Ignee, G. Schuessler, C. F. Dietrich

21.1 Indications ... 215

21.2 Contraindications ... 215

21.3 Materials and Equipment ... 215

21.4 Types of Gastrostomy ... 215

21.4.1 Percutaneous Endoscopic Gastrostomy ... 215

21.4.2 Percutaneous Sonographic Gastrostomy ... 216

21.5 Advantages and Disadvantages of Different Methods ... 216

21.6 Success Rates of Different Gastrostomy Techniques ... 216

21.7 Complication Rates of Different Gastrostomy Techniques ... 216

21.8 Role of Ultrasonography ... 217

21.8.1 General ... 217

21.8.2 Ultrasound-Assisted PEG ... 218

21.8.3 Technique of Percutaneous Sonographic Gastrostomy ... 219

21.9 Questions Relevant to Percutaneous Sonographic Gastrostomy ... 220

21.9.1 Use of a Spasmolytic Agent ... 220

21.9.2 Prophylactic Antibiotics ... 220

21.9.3 Use of a Guidewire ... 220

21.9.4 Need for Gastropexy ... 220

21.9.5 Type of Drainage ... 221

21.10 Summary ... 222

References ... 223

22 Interventional Endosonography ... 224
C. F. Dietrich, M. Hocke, C. Jenssen

22.1 Cost–Benefit Analysis ... 224

22.2 Historical Introduction ... 224

22.3 Materials and Equipment ... 224

22.3.1 Requirements of the Endoscopy Unit ... 224
22.3.2 Which Endosonography Systems Have Become Established? ... 225
22.3.3 Which Biopsy Needles and Techniques Have Become Established? ... 225
22.3.4 Guidewires ... 227
22.3.5 Fixed-Diameter Dilators ... 228
22.3.6 Balloon Dilators ... 229
22.3.7 Plastic Stents (Pigtail) ... 230
22.3.8 Metal Stents ... 231
22.3.9 Diathermy Devices, Cystotome ... 232
22.3.10 Retrievers ... 233
22.3.11 Supplementary Techniques in EUS-guided Biopsy ... 234

22.4 Procedure ... 234

22.4.1 Sedation ... 234
22.4.2 Other Medications ... 234
22.4.3 Orientation ... 234
22.4.4 General Rules for Needle Insertion ... 234
22.4.5 Biopsy Technique ... 235
22.4.6 Suction ... 235
22.4.7 Specimen Processing ... 235

22.5 Diagnostic Interventions ... 236

22.5.1 Indications ... 236
22.5.2 Risk of Complications ... 237
22.5.3 Contraindications ... 238

22.6 Therapeutic Interventions, General Aspects ... 238

22.6.1 Therapeutic EUS-Guided Interventions ... 238
22.6.2 Endoscopes and Needle Types ... 238
22.6.3 General Rules for Needle and Wire Handling ... 239
22.6.4 Indications ... 239
22.6.5 Contraindications ... 239

22.7 Drainage of Peripancreatic Fluid Collections ... 239

22.7.1 History ... 239
22.7.2 Basic Anatomical Considerations ... 239
22.7.3 Pathophysiologic Considerations ... 239
22.7.4 Diagnostic Workup ... 239
22.7.5 Indications ... 240
22.7.6 Timing of the EUS Intervention ... 240
22.7.7 Selection of Procedure ... 240
22.7.8 Technique ... 240
22.7.9 One-Step Systems ... 240
22.7.10 Treatment of Nonpancreatic Fluid Collections ... 242
22.7.11 Surgical Options ... 243

22.8 EUS-Guided Cholangiodrainage ... 243

22.8.1 Introduction ... 243
22.8.2 Indications and Treatment Goals ... 244
22.8.3 Equipment ... 244
22.8.4 Preparatory Measures ... 244
22.8.5 Technique ... 244
22.8.6 Assessing the Result, Postinterventional Care, Complications ... 246

22.9 EUS-Guided Pancreatic Duct Drainage ... 246

22.9.1 Indications and Treatment Goals ... 246
22.9.2 Technique ... 246
22.9.3 Assessing the Result, Postinterventional Care, Complications ... 246

22.10 Celiac Plexus Neurolysis and Celiac Plexus Blockade ... 246

22.10.1 Indications and Treatment Goals ... 246
22.10.2 Materials ... 247
22.10.3 Technique ... 247
22.10.4 Assessing the Result, Postinterventional Care, Complications ... 247

22.11 Tumor Ablation with Alcohol ... 247

22.12 EUS-Guided Vascular Interventions ... 248

22.12.1 Indications and Treatment Goals ... 248
22.12.2 Materials ... 248
22.12.3 Technique ... 248
22.12.4 Assessing the Result, Postinterventional Care, Complications ... 248

22.13 Complications ... 249

22.14 Postinterventional Care ... 250

References ... 251

23 Special Issues Regarding Interventions in the Spleen 254
C. F. Dietrich

23.1 Diffuse Splenic Changes 254

23.2 Specific Disorders 254

23.2.1 Splenic Rupture 254
23.2.2 Splenic Infarction 254
23.2.3 Focal Splenic Changes 255

23.3 Procedures 255

23.3.1 Clinical Scenarios 255
23.3.2 Anatomical Considerations in Splenic Interventions 255
23.3.3 Procedures for Specific Applications 256

23.4 Abscess Drainage 256

23.5 Indications 256

23.6 Contraindications 256

23.7 Indications for Splenic Biopsy Drawn from Case Data 256

23.8 Postinterventional Care 257

23.9 Complications 257

23.10 Preinterventional Vaccinations 257

References 257

Specific Ultrasound-Guided Procedures: Thorax

24 Thoracic Interventions 260
W. Blank, A. Heinzmann

24.1 Advantages of Ultrasound-Guided Interventions 260

24.2 Indications 261

24.3 Contraindications 261

24.4 Selection of Materials 261

24.4.1 Ultrasound Technology 261
24.4.2 Biopsy Devices 262

24.5 Preparations 263

24.6 Technique 264

24.6.1 Chest Wall Lesions 264
24.6.2 Pleural Space 264
24.6.3 Subpleural Lung Lesions 265
24.6.4 Pulmonary Abscesses 268
24.6.5 Mediastinum 268

24.7 Steps in the Procedure 269

24.7.1 Preparations 269
24.7.2 Technique 269
24.7.3 Postprocedure Care 269

24.8 Problems and Complications 269

24.8.1 Postbiopsy Pneumothorax 269

24.9 Postprocedure Care and Follow-Up 270

References 271

Specific Ultrasound-Guided Procedures: Urogenital System

25 Percutaneous Renal Biopsy 274
U. Goettmann, B. K. Kraemer

25.1 Indications 274

25.2 Contraindications 274

25.3 Materials and Equipment 275

25.4 Preparations 275

25.5 Procedure 276

25.5.1 Native Renal Biopsy 276
25.5.2 Review of the Procedure Steps 277
25.5.3 Biopsy of a Renal Allograft 277

25.6 Complications 277

25.7 Postbiopsy Care 278

25.8 List of Materials and Equipment 278

References 278

26 Interventional Urology 280

D. Brix, A. Ignee, C. F. Dietrich

26.1 Transrectal Ultrasonography of the Prostate 280

26.1.1 Introduction 280
26.1.2 Equipment Requirements 280

26.2 Diseases of the Prostate 280

26.2.1 Prostate Cancer 280
26.2.2 Prostatic Abscess 281

26.3 Prostate Biopsy 281

26.3.1 Introduction 281
26.3.2 Indications 281
26.3.3 Informed Consent and Preparation 281
26.3.4 Complications and Their Management . . . 281
26.3.5 Transperineal Biopsy 282

26.4 Percutaneous Nephrostomy 282

26.4.1 Introduction 282
26.4.2 Indications 282
26.4.3 Relative Contraindications 282
26.4.4 Complications 282
26.4.5 Preparations 282
26.4.6 Materials and Equipment 282
26.4.7 Technique 282
26.4.8 Anesthesia 283
26.4.9 Procedure 283
26.4.10 Postoperative Care 284
References 285

Specific Ultrasound-Guided Procedures: Other Organ Systems

27 Interventional Thyroid Ultrasound 288

B. Braun, T. Mueller

27.1 Diagnostic Interventions 288

27.1.1 Indications 288
27.1.2 Contraindications 288
27.1.3 Methods 288
27.1.4 Complications 290
27.1.5 Materials and Equipment 290
27.1.6 Preparation 291
27.1.7 Procedure 292
27.1.8 Problems 293
27.1.9 Pitfalls in Thyroid Biopsy 294

27.2 Therapeutic Interventions 295

27.2.1 Evacuation Procedures 296
27.2.2 Ablative Procedures 296
References 301

28 Musculoskeletal Interventions 304

W. Hartung, T. Weigand

28.1 Indications and Contraindications 304

28.1.1 Indications 304
28.1.2 Contraindications 304

28.2 Materials and Equipment 304

28.3 Procedure 305

28.3.1 Preparations 305
28.3.2 Overview of Technique 306
28.3.3 Details of Technique 306
28.3.4 Rotator Cuff (Supraspinatus Muscle) 309

28.4 Pitfalls and Complications 312

28.5 Postprocedure Care 313

References 313

29 Neurologic Interventions, Ultrasound-Guided Regional Anesthesia 315

H. H. Wilckens, A. Ignee, M. Kaeppler, H. Boehrer, C. F. Dietrich

29.1 History and Development 315

29.2 Indications 315

29.3 Contraindications 315

29.3.1 Patient Refusal 315
29.3.2 Clinically Overt Coagulopathy and Anticoagulant Medication 315
29.3.3 Infections at the Puncture Site 316
29.3.4 Neurologic Deficit 316

29.4 Needle Insertion Techniques 316

29.4.1 Out-of-Plane versus In-Plane Technique 316

29.5 Ultrasound Imaging of Nerves and Muscles 316

29.5.1 Nerves 316
29.5.2 Muscles 317

29.6 Materials and Equipment 317

29.6.1 Ultrasound Machines 317
29.6.2 Anesthesia Needles and Catheters 317

29.7 Regional Anesthesia at Specific Sites: Upper Limb 318

29.7.1 Brachial Plexus 318
29.7.2 Infraclavicular Brachial Plexus Block 320
29.7.3 Axillary Brachial Plexus Block 321

29.8 Regional Anesthesia at Specific Sites: Lower Limb 322

29.8.1 Lumbosacral Plexus 322
29.8.2 Femoral Nerve Block 323
29.8.3 Obturator Nerve Block 323
29.8.4 Sciatic Nerve Block 325
29.8.5 Saphenous Nerve Block 326
29.8.6 Lateral Femoral Cutaneous Nerve Block 326

29.9 Summary 327

References 328

30 Ultrasound-Guided Emergency and Vascular Interventions 330

T. Mueller, C. Jenssen

30.1 Emergency Interventions 330

30.1.1 Indications 330
30.1.2 Contraindications 331
30.1.3 Materials and Equipment 331
30.1.4 Antisepsis 332
30.1.5 Problems and Complications 332
30.1.6 Intra-abdominal Free Fluid 332
30.1.7 Intrathoracic Free Fluid 333
30.1.8 Pneumothorax 333
30.1.9 Pericardial Fluid 334

30.2 Percutaneous Vascular Interventions 335

30.2.1 Vascular Access 335
30.2.2 Ultrasound-Guided Treatment of Pseudoaneurysms 341

30.3 Endosonographically Guided Vascular Interventions 345

30.3.1 Indications and Treatment Goals 345
References 348

Specific Ultrasound-Guided Procedures: Other Applications of Interventional Ultrasound

31 Extravascular Use of Ultrasound Contrast Agents 354

A. Ignee, G. Schuessler, C. F Dietrich

31.1 Approved Indications 354

31.2 Contraindications and Complications 354

31.3 Technique 354

31.4 Use of Ultrasound Contrast Agents in Physiologic Body Cavities 355

31.4.1 Voiding Sonography for the Detection of Vesicoureteral Reflux 355
31.4.2 Contrast-Enhanced Ultrasound for Evaluating Tubal Patency 355
31.4.3 Imaging the Peritoneal Cavity with UCAs (for Detection of Ascites) 355
31.4.4 Biliary Tract 356
31.4.5 UCAs in Enterography 356
31.4.6 CEUS Gastrography—Percutaneous Injection of UCA into the Stomach to Assess Gastrostomy Placement 356

31.5 Use of Ultrasound Contrast Agents in Nonphysiologic Body Cavities 356

31.5.1 Ultrasound Fistulography 356
31.5.2 Percutaneous Injection of UCAs for Abscess Imaging 357
31.5.3 UCAs for Demonstrating Pancreatitis-Associated Cystic Lesions after EUS-Guided Biopsy 357

31.6 Summary 357

References 358

32 Volume Navigation 359

C. F Dietrich, A. Ignee, M. Hoepfner

32.1 How Tracking Works 359

32.2 Position Marking 359

32.3 Fusion with CT, MRI, or PET Volume Data Sets 359

32.4 Fusion with Archived Ultrasound Volume Data 362

32.5 Magnetic Field–Assisted Needle Tracking and Guidance 362

32.6 Illustrative Images and Case Reports 362

32.6.1 Case Report 1 362
32.6.2 Case Report 2 362
References 363

33 Palliative Interventions and the Role of Ultrasonography in Palliative Care 364

D. Nuernberg

33.1 Content and Goals of Palliative Care . . . 364

33.2 Ultrasound in Palliative Staging, Follow-Up, and Palliative Treatment Monitoring 364

33.3 Ultrasound-Guided Palliative Interventions 365

33.3.1 Palliative Diagnostic Interventions 365
33.3.2 Specific Palliative Therapeutic Interventions 366

33.4 Portable Ultrasound in Specialized Ambulatory Palliative Care 367

33.5 Palliative Ultrasound in Caring Medicine 367

33.6 Conclusions 368

References 368

Index 369

Foreword

Surprisingly, no comprehensive textbook has been written on the topic of ultrasound guidance of interventional procedures. This may be because ultrasound use in different specialties or subspecialties is so broad and is expanding that is difficult to complete a comprehensive and timely text on the subject matter. Ultrasound is now used to guide interventional techniques by practitioners in nearly every specialty, including cardiology, radiology, intensive care, anesthesiology, gastroenterology, and others. For this reason it is difficult to collect all of the relevant knowledge and information into a single text. Fortunately, Christoph Dietrich and Dieter Nuernberg have undertaken to do this. Their joint skills as clinicians, teachers, and authors have produced an important textbook of interventional ultrasound. The coauthors of each chapter were carefully chosen to reflect their discipline with expertise in their particular field of interest. Together they have completed a comprehensive text on traditional methods of ultrasound guidance of interventional techniques and have included newer and more advanced use of ultrasound in guiding other techniques. They have also reviewed more recent advances in interventional ultrasound including the use of contrast agents that help identify, guide, and assess the success of different interventional procedures. Certainly ultrasound has been shown to have various advantages over other modalities such as CT in guiding interventional procedures. Ultrasound transducers have been adapted for endoscopic use and are now routinely used in biopsy of the thorax and the gastrointestinal tract. Many percutaneous biopsy aspiration or drainage techniques are now performed with ultrasound instead of CT because of the real-time capabilities, lack of ionizing radiation, and precision of sonographic needle placement. Furthermore, advanced ablative techniques can be guided by sonography, and the use of modern ultrasound contrast agents allows assessment of the adequacy of tumor ablation after treatment.

The authors first take us back in time with a historical perspective of the use of interventional ultrasound, then deal comprehensively with current technologies, and take us forward to future applications of ultrasound in different subspecialties.

I am very pleased to have been asked to write the foreword for this work because I believe this textbook on interventional ultrasound will be used as a standard reference text in this field. It gives both historical perspectives and up-to-date information on the use of ultrasound in guidance of different interventional techniques. The authors and the editors deserve congratulations for the completion of this important work.

John P. McGahan, MD
Professor and Vice Chair of Academic Affairs
Director of Abdominal Imaging
Department of Radiology
University of California, Davis, USA

Preface

Interventional ultrasound procedures have revolutionized clinical practice in recent decades. The advantages of ultrasound-guided interventions include an unsurpassed sharpness of detail and excellent controllability due to the real-time visual display, the wide availability of ultrasound equipment, and a simple and straightforward practical technique. This makes it all the more surprising that a standard textbook of interventional ultrasound has not previously been published.

The editors have accessed a wealth of experience from their expert contributors, who present the subject matter as concretely as possible and offer vivid descriptions of practical techniques. Particular attention is given to clinical significance.

The practice-oriented approach may have caused some instruments to be emphasized over other tested and proven devices, with the result that some reputable companies and their products were not given due attention.

The experience presented here, while proven, is often highly individualized. In future editions, it is intended that the content will be enhanced by input from ultrasound interventionalists who have not contributed to this book so that we may achieve a fuller and more balanced presentation. The advantage of a concrete, detailed chapter format is obvious, and the editors hope to see this work used as a "cookbook" in the everyday practice of interventional ultrasound.

The book consists of two main parts. Part I deals with general aspects of interventional ultrasound, Part II with specific ultrasound-guided procedures. Part I begins with a historical review, which is necessary for the understanding of some current techniques. Next come chapters that present essential basic information on interventional materials, issues of informed consent, equipment requirements, on-site material processing, microbiological aspects, and issues relating to hygiene and management of complications. The importance of assisting personnel is too often overlooked: this is addressed in a separate chapter and under specific subheads. Particularly in oncology, histologic (and/or cytologic) confirmation is essential for planning a highly specialized and differentiated modern treatment strategy. Up-to-date immunohistochemical and immunocytologic staining methods and proliferation indices are essential aids to directing the treatment of gastrointestinal stromal tumors and other lesions. Lymphomas are classified hematologically as low-grade, aggressive, or highly aggressive lesions, with each type having its own therapeutic implications. The knowledge of contraindications, complication management, and how to weigh risks against benefits forms the basis for the chapters presented.

Part II deals with pulmonary biopsy techniques and thoracic interventions as well as diagnostic and therapeutic interventions involving the thyroid gland, urogenital tract, and musculoskeletal system. Endosonographic interventions are described in detail. Other topics relate to combined radiologic and sonographic interventions as well as critical-care and emergency-room interventions including cardiologic and anesthesiologic procedures. Part II also explores interventions in children and takes a look at new techniques and future perspectives. Symptom-oriented palliative care interventions represent a very topical issue that rounds out the chapter. Therapeutic abscess drainage, interventional tumor ablation techniques, and interventional treatments for parasitic diseases (PAIR [puncture, aspiration, injection, reaspiration] for echinococcosis) enrich our daily practice, as do established therapeutic procedures such as percutaneous transhepatic cholangiography and drainage (PTCD), nephrostomy, and the drainage of pancreatic pseudocysts. In the matter of interventional guidance and approach, it is often necessary to decide between the competing modalities of CT guidance and other imaging techniques, which in some case can and should be used to complement or supplement one another. The role of ultrasound contrast agents in the preparation, support, and guidance of interventional procedures is also addressed.

This book is an expression of interdisciplinary and multiprofessional viewpoints, some of which represent different approaches; this reflects reality in all its diversity. The principle of "do no harm" is expressed in repeated urgings to apply the techniques judiciously in everyday practice and not to become fascinated with technology for its own sake. The decision to proceed with an intervention is always an individual one and should be measured by its benefit for the patient.

Professor Christoph F. Dietrich, MD
Professor Dieter Nuernberg, MD

Acknowledgments

Many experts had a hand in the creation of this book. This is evident from the list of distinguished authors. While the chapters were being written all contributions were subject to intense critical discussion by our circle of colleagues who contributed many important and very helpful suggestions and reviews on specific chapters. Some of these colleagues were outside the circle of our authors, and we wish to thank them by name for their extremely valuable feedback and commitment:

Ana Paula Barreiros, MD
Professor Joerg Bleck, MD
Bettina Fiedler, MD
Professor Christian Goerg, MD
Professor Martin Krueger, MD
Birgitt Lucke
Professor Juergen F. Riemann, MD
Christiane Schieferstein, MD
Professor Wolf Burkhardt Schwerk, MD
Professor Hanns M. Seitz, MD
Jochen Selbach, MD
Stephan Wagner, MD
Professor Till Wehrmann, MD
Matthias Woenchkaus, MD
Kriztina Zels

In addition, we thank Dr. Thomas Riebel and Dr. Holger Strunk for their valuable contribution to the orginal German edition.

We express our sincere thanks to Mrs. Kerstin Siehr, Dr. Michael Weber, Dr. Katrin Gottloeber, Dr. Stefanie Eylert, and Dr. Tiberius Maros for their tireless support whenever a little help was needed. We thank Dr. Lilian Chiorean for her proofreading and bright ideas. We also thank the team at Thieme Publishers Stuttgart, particularly acknowledging Dr. Brands for his swift decisions as well as Dr. Tegude, Mrs. Holzer, Joanne Stead, Stephan Konnry, and Gabriele Kuhn-Giovannini for their friendly and efficient work in project management and production.

Contributors

Thomas Albrecht, MD
Professor
Department of Radiology and Interventional Therapy
Vivantes Hospital Neukölln
Berlin, Germany

Thomas Bernatik, MD
Professor and Director
Department of Internal Medicine, Gastroenterology
Specialist in Internal Medicine and Diabetology
Ebersberg County Hospital
Ebersberg, Germany

Thomas Beyer, MD
Ballenstedt-Harz Lung Clinic GmbH
Ballenstedt, Germany

Wolfgang Blank, MD
Supervising Physician and Deputy Head Physician
Medical Clinic 1
Klinikum am Steinenberg Hospital
Reutlingen, Germany

Hubert Boehrer, MD
Professor
Department of Anesthesiology and Critical Care Medicine
Caritas Hospital Bad Mergentheim gGmbH
Bad Mergentheim, Germany

Barbara Braden, MD
Professor
Consultant Gastroenterologist
Translational Gastroenterology Unit
John Radcliffe Hospital
Oxford, UK

Bernd Braun, MD
Professor and former Head Physician
Medical Clinic 1
Klinikum am Steinenberg Hospital
Reutlingen, Germany

David Brix, MD
Department of Urology
Caritas Hospital Bad Mergentheim gGmbH
Bad Mergentheim, Germany

Xin Wu Cui
Medical Clinic 2
Caritas Hospital Bad Mergentheim gGmbH
Bad Mergentheim, Germany

Christoph F. Dietrich, MD
Professor and Head Physician
Medical Clinic 2
Caritas Hospital Bad Mergentheim gGmbH
Bad Mergentheim, Germany

Thomas Glueck, MD
Professor
Department of Internal Medicine
Trostberg District Hospital – Kliniken SO-Bayern
Trostberg, Germany

Uwe Goettmann, MD
Professor
Consultant Nephrologist
Medical Clinic V
University Medical Center Mannheim
Mannheim, Germany

Uwe Gottschalk, MD
Center for Liver Diseases at Checkpoint
Berlin, Germany

Wolfgang Hartung, MD
Department of Rheumatology and Clinical Immunology
Asklepios Hospital Bad Abbach
Regensburg University Care Network
Bad Abbach, Germany

Alexander Heinzmann, MD
Chief Physician
Medical Clinic I
Klinikum am Steinenberg Hospital
Reutlingen, Germany

Michael Hocke, MD
Department of Internal Medicine II
Meiningen Hospital GmbH
Meiningen, Germany

Michael Hoepfner, MD
Department of Medicine
Rotes Kreuz Hospital Kassel
Kassel, Germany

Andre Ignee, MD
Medical Clinic 2
Caritas Hospital Bad Mergentheim gGmbH
Bad Mergentheim, Germany

Christian Jenssen, MD
Department of Internal Medicine
Mrkisch-Oderland Hospital GmbH
Strausberg, Germany

Adelheid Jung, MD
Medical Clinic B
Ruppiner Hospitals GmbH
Neuruppin, Germany

Joerg-Carsten Kaemmer, MD
Department of Internal Medicine
St. Hedwig Hospital
Berlin, Germany

Michael Kaeppler, MD
Department of Anesthesiolgy and Critical Care Medicine
Caritas Hospital Bad Mergentheim gGmbH
Bad Mergentheim, Germany

Horst Kinkel, MD
Medical Clinic II
Düren Hospital GmbH
Düren, Germany

Bernhard Karl Kraemer, MD
Professor and Head Physician
Medical Clinic V
University Medical Center Mannheim
Mannheim, Germany

Hans-Joerg Linde, MD
Beratzhausen, Germany

Harald Lutz, MD
Professor
Bayreuth, Germany

Heike Martiny, PhD
Technical Hygiene
Benjamin Franklin Campus
Charit Medical University
Berlin, Germany

Thomas Mueller, MD
Medical Clinic I
Klinikum Am Steinenberg Hospital
Reutlingen, Germany

Dieter Nuernberg, MD
Professor and Head Physician
Medical Clinic B
Ruppiner Hospitals GmbH
Neuruppin, Germany

Gudrun Schuessler
Department of Medicine
Caritas Hospital Bad Mergentheim gGmbH
Bad Mergentheim, Germany

Andrea Tannapfel, MD
Professor
Institute of Pathology
Ruhr-University Bochum
Bochum, Germany

Thomas Weigand, MD
Joint Practice in General and Internal Medicine and Rheumatology
Bad Abbach, Germany

Hans-Hinrich Wilckens
Department of Anesthesiology
Heidelberg University Hospital
Heidelberg, Germany

Abbreviations

5-FU	5-fluorouracil
AASLD	American Association for the Study of Liver Diseases
AFP	alpha-fetoprotein
AgNOR	argyrophilic nuclear organizer regions
AGO	Arbeitsgemeinschaft Gynkologische Onkologie
aPTT	activated partial thromboplastin time
ARDMS	American Registry of Diagnostic Medical Sonographers
ASA	acetylsalicylic acid; aspirin
ASA	American Society of Anesthesiologists
ATLS	advanced trauma life support
BCLC	Barcelona Clinic Liver Cancer (staging system)
BP	blood pressure
BW	body weight
CCC	cholangiocellular carcinoma
CDS	color duplex sonography
CEA	carcinoembryonic antigen
CELMIEUS	contrast-enhanced low MI endoscopic ultrasound
CEUS	contrast-enhanced ultrasonography
CIN	cervical intraepithelial neoplasia
CK	cytokeratin
CMV	cytomegalovirus
CNS	central nervous system
COPD	chronic obstructive pulmonary disease
CPB	celiac plexus blockade
CPN	celiac plexus neurolysis
CRP	C-reactive protein
CUP	carcinoma of unknown primary
CVC	central venous catheter
DDAVP	1-deamino-8-d-arginine vasopressin [desmopressin]
DES	drug-eluting stents
DLCL	diffuse large cell lymphomas
DPAM	diffuse peritoneal adenomucinosis
EASL	European Association for the Study of the Liver
EBUS-TBNA	endobronchial ultrasound-guided transbronchial needle aspiration
EBV	Epstein-Barr virus
ECG	electrocardiogram/electrocardiography
ECOG PS	Eastern Cooperative Oncology Group. Performance Status
EDV	end diastolic velocity
EGFR	epithelial growth factor receptor
ELISPOT	enzyme-linked immunospot
EMA	epithelial membrane antigen
ER	estrogen receptor
ERC	endoscopic retrograde cholangiography
ERCP	endoscopic retrograde cholangiopancreatography
ESA	European Society of Anesthesiology
ESBL	extended-spectrum beta-lactamase
ESGE	European Society of Gastrointestinal Endoscopy

ESGENA	European Society of Gastroenterology and Endoscopy Nurses and Associates
ESR	erythrocyte sedimentation rate
EUS	endoscopic ultrasound
EUS-CD	EUS-guided chiolangiogrpahy and drainage/cholangiodrainage
EUS-CPB	EUS-guided celiac plexus block
EUS-CPN	EUS-guided celiac plexus neurolysis
EUS-FNA	endoscopic ultrasound-guided FNA; endoscopic ultrasonography with fine needle aspiration
EUS-FNB	endoscopic ultrasonography with fine-needle biopsy
EUS-PD	EUS-guided pancreatic duct drainage
EUS-TCB	EUS-guided Trucut biopsy
EVCEUS	extravascular contrast-enhanced ultrasound
FAST	focused assessment with sonography for trauma
FFP	fresh frozen plasma
FISH	fluorescence in situ hybridization
FNA	fine needle aspiration
FNAB	fine needle aspiration biopsy
FNAC	fine needle aspiration cytology
FNB	fine needle biopsy
FNC	fine needle cytology
FNH	focal nodular hyperplasia
fT_3	free triiodothyronine
fT_4	free thyroxine
GIST	gastrointestinal stromal tumors
GP	glycoprotein
HAV, HBV, HCV, HDV, HEV	hepatitis A, B, C, D, E virus
HCC	hepatocellular carcinoma
HCG	human chorionic gonadotropin
HDPE	high-density polyethylene
Hep Par 1	hepatocyte paraffin 1
HES	hydroxyethyl starch
HGFR	hormone growth factor receptor
HIFU	high-intensity focused ultrasound
HIPEC	hyperthermic intraperitoneal chemotherapy
HIV	human immunodeficiency virus
HLC	hepatosplenic candidiasis
HMWK	high–molecular weight kininogen
HRPC	hormone-refractory prostate cancer
HU	Hounsfield Unit
HyCoSy	hysterosalpingo-contrast sonography
IGCNU	intratubular germ cell neoplasia, unclassified
IHAT	indirect hemagglutination antibody test
INR	international normalized ratio
IP	intraperitoneal
LCA	leukocyte common antigen
LDH	lactate dehydrogenase
LDPE	low-density polyethylene
LITT	laser-induced thermotherapy
LLD	left lateral decubitus
LLDPE	linear low-density polyethylene

LMWH	low–molecular-weight heparin
MALT	mucosa-associated lymphatic tissue
MCP	metacarpophalangeal
MGG	May–Grünwald–Giemsa
MHEMS	Mobile Hospital Emergency Medical System
MI	mechanical index
MIB-1	monoclonal antibody against Ki-67
MOTT	mycobacteria other than tuberculosis
MRCP	magnetic resonance cholangiopancreaticography
MWA	microwave ablation
NAPS	nurse-administered propofol sedation
NASH	nonalcoholic steatohepatitis
NHL	non-Hodgkin lymphoma
NOAC	novel oral anticoagulants
NPV	negative predictive value
NSAID	nonsteroidal anti-inflammatory drug
NSE	neuron-specific enolase
NTM	nontuberculous mycobacteria
PACS	picture archiving and communication system
PAD	percutaneous abscess drainage
PAI	percutaneous acetic acid injection
PAIR	puncture–aspiration–injection of alcohol–reaspiration
PanIN	pancreatic intraepithelial neoplasia
PBC	primary biliary cirrhosis
PCN	percutaneous nephrostomy
PCR	polymerase chain reaction
PCT	palliative care teams
PEG	percutaneous endoscopic gastrostomy
PEI	percutaneous ethanol injection
PFA	platelet function assay
PIN	prostatic intraepithelial neoplasia
PLA	percutaneous laser ablation
PMCA	aggressive peritoneal mucinous carcinomatosis
PNL	percutaneous nephrolitholapaxy
PPD	purified protein derivative [of tuberculin]
PPV	positive predictive value
PRG	percutaneous radiologic gastrostomy
PSA	prostate-specific antigen
PSAP	prostate-specific acid phosphatase
PSC	primary sclerosing cholangitis
PSG	percutaneous sonographic gastrostomy
PSV	peak diastolic velocity
PTA	percutaneous transluminal angioplasty
PTC	percutaneous transhepatic cholangiography
PTCD	percutaneous transhepatic cholangiography and drainage; percutaneous transhepatic cholangiodrainage
PTFE	polytetrafluoroethylene (Teflon)
PTLD	posttransplant lymphopoliferative disease
PTT	partial thromboplastin time
PVP	polyvinylpyrrolidone
RCAP	resistance-controlled automatic power

RCC	renal cell carcinoma
RFA	radiofrequency ablation
RFITT	radiofrequency-induced thermotherapy
RFTA	radiofrequency thermoablation
ROSE	rapid on-site evaluation
SAPV	specialized ambulatory palliative care
SBP	spontaneous bacterial peritonitis
SDMS	Society of Diagnostic Medical Sonography
SIRT	selective internal radiotherapy
SLE	systemic lupus erythematosus
SMA	smooth muscle actin
TACE	transarterial chemoembolization
TB	tuberculosis
THI	tissue harmonic imaging
TIA	transient ischemic attack
TIPS	transjugular intrahepatic portosystemic shunt
TIPSS	transjugular intrahepatic portosystemic stent shunt
TPCD	transpapillary cholangiodrainage
TPHA	Treponema pallidum hemagglutination
TRUS	transrectal ultrasonography
TSH	thyroid-stimulating hormone
TTF-1	thyroid transcription factor 1
TURP	transurethral resection of the prostate
UCA	ultrasound contrast agent
UICC	Union for International Cancer Control/Union Internationale Contre le Cancer
US-FNA	ultrasound-guided FNA
VAH	Association for Applied Hygiene
VaIN	vaginal intraepithelial neoplasia
VDRL	Venereal Disease Research Laboratory [test for syphilis]
VEGFR	vascular endothelial growth factor receptor
VIN	vulval intraepithelial neoplasia
VKA	vitamin K antagonist
VRE	vancomycin-resistant enterococci
VTE	venous thromboembolism
WBC	white blood cell count

General Aspects of Interventional Ultrasound

1 Interventional Ultrasound: Introduction and Historical Background . . . 2

2 Interventional Materials and Equipment . . . 13

3 Informed Consent . . . 32

4 Medications, Equipment, and Setup Requirements . . . 35

5 Pathology and Cytology . . . 40

6 Fine Needle Aspiration Cytology . . . 49

7 Infections and Diagnostic Microbiology . . . 68

8 Hygiene Management . . . 82

9 Contraindications, Complications, and Complication Management . . . 86

10 Assistance in Ultrasound Interventions . . . 109

11 Sedation in Interventions . . . 114

1 Interventional Ultrasound: Introduction and Historical Background

H. Lutz

1.1 The Vienna Congress

The "First World Congress on Ultrasonic Diagnostics in Medicine" was held in Vienna in 1969. It marked the end of the pioneering age of diagnostic ultrasound that began after World War II. By that time ultrasonography had already found applications in ophthalmology as well as neurology (echoencephalography using A-mode ultrasound to detect intracranial hemorrhage, for example) and cardiology (TM-mode echocardiography for diagnosing valvular disease). Especially for the fields of obstetrics, gynecology, and internal medicine, the Congress marked the start of a burgeoning period of clinical research.

The Vienna Congress began as the Third International Symposium on Ultrasonic Diagnostics in Ophthalmology (SIDUO III) headed by Viennese ophthalmologists J. Böck, who served as president, and K. Ossoinig, who served as scientific secretary. The original symposium was changed to an interdisciplinary world conference when it was recognized that, for the first time, comprehensive reports on diagnostic ultrasound were available from a number of other specialties. A total of 190 papers were presented—48 in ophthalmology, 29 in neurology, 20 in cardiology, 19 in obstetrics and gynecology, and 23 in internal medicine.

Only two papers dealt with the capabilities of ultrasound-guided needle procedures, and both reflected the full spectrum of possible procedures and future diagnostic applications. A. Kratochwil[1] reported on ultrasound-guided amniocentesis using a specially designed biopsy transducer (▶ Fig. 1.1).

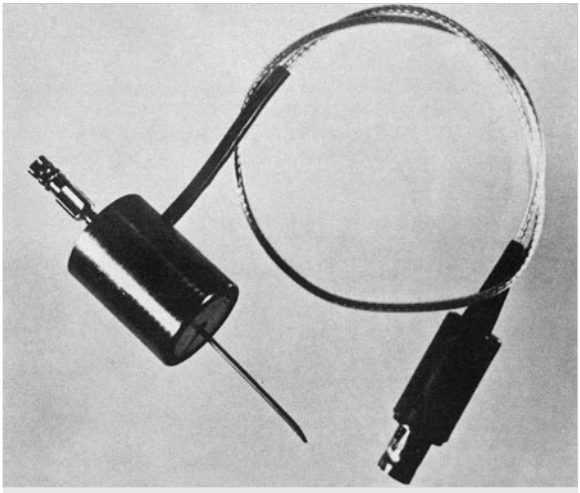

Fig. 1.1 A-mode transducer with a central aperture for guiding the (amniocentesis) needle, introduced by Kratochwil in Vienna in 1969. (Source: With kind permission of the Vienna Medical Academy.[1])

U. W. Blauenstein used ultrasound to localize tumor nodules in the liver and puncture them percutaneously, aided by markings drawn on the skin (▶ Fig. 1.2).[2]

To appreciate the significance of these reports, we must recall the conventional diagnostic tools that were available at that time. The relatively simple percutaneous drainage of relatively large fluid collections was traditionally guided by anatomical landmarks (e.g., for draining ascites) or percussion (e.g., for thoracentesis). But these methods were difficult or impossible to use in patients with small fluid collections, adhesions, or septations. A relatively large organ like the liver could be sampled to investigate presumed diffuse disease using a standard technique following localization by percussion. The development of the Menghini needle in 1958 had made percutaneous liver biopsy a simple procedure.[3] On the other hand, a suspected tumor was considered at least a relative contraindication to needle biopsy, so that technique could not be used for the selective sampling of tumor nodules in the liver.

The only imaging modality available at that time for the percutaneous biopsy of nonpalpable organs and structures was classical radiography. But this method was problematic for several reasons. First, the relationship of the intended target (e.g., the inferior renal pole) to anatomical landmarks like the spinal column was measurable but the distance from skin to target (i.e., the second plane) was not. Moreover, the kidney had to have sufficient residual function that it could be opacified by intravenous contrast medium. Radiographic imaging also required costly radiation safety measures for the patient and staff.

Kratochwil described in his paper how ultrasound guidance could make standard needle procedures easier and safer (here, by avoiding the placenta), even in unusual situations. The sectional images produced by ultrasonography enable the target site to be visualized and localized in all three dimensions. As early as 1961, G. M. Berlyne[4] suggested that the two-dimensional pyelogram obtained before percutaneous renal biopsy could be supplemented by an A-mode scan to measure the depth from skin to target. In 1970, G. Rettenmaier noted the advantages of using two-dimensional real-time ultrasound to track the respiratory movements of the kidney and provide a third localizing dimension.[5]

Martin and Ellis[6] were the first authors to report on the aspiration biopsy of suspected neoplasms. Traditionally, however, a targeted aspiration biopsy could be used only



Fig. 1.2 Example of an ultrasound-guided percutaneous liver biopsy. Same-scale views of the skin site and ultrasound image as presented by Blauenstein in Vienna in 1969. X marks the skin entry site over the enlarged hepatic left lobe. (Source: With kind permission of the Vienna Medical Academy.[2])

for palpable masses, thoracic tumors accessible to radiographic guidance, or during (exploratory) laparotomy.

Blauenstein was the first author to show that ultrasound could be used not only to identify suspicious lesions in organs but also to biopsy them selectively for further differentiation. Thus began the development of a relatively simple diagnostic method for the detection and differentiation of even small, nonpalpable suspected neoplasms. By that time authors had already reported positive experience with the cytologic analysis of material sampled by percutaneous aspiration (e.g., from lymph nodes, the thyroid gland, the breast, or lung tumors) and of tumor lesions (e.g., of the pancreas) sampled by intraoperative needle biopsy.

Meanwhile, both Kratochwil and Blauenstein had demonstrated the two main options available for performing ultrasound-guided punctures. Blauenstein used a kind of freehand technique in which he first measured the location of the intended target and marked it on the skin, then advanced the needle to the target without observing it directly (▶ Fig. 1.2). Kratochwil used a special biopsy transducer (▶ Fig. 1.1), which provided an A-mode display of the structures (in this case the placenta) previously defined by a slow B-mode scan.

1.2 The Introduction of Ultrasound into Routine Clinical Use

1.2.1 The Evolution of Ultrasound Imaging Techniques

Over the next 10 to 15 years, two-dimensional sectional imaging with ultrasound was increasingly implemented in almost all medical specialties. At first the bistable compound scan was still the (international) standard and was supplemented by A-mode scanning for "structural" analysis. The introduction of gray-scale technology in 1974 significantly improved the images generated by this type of system. Even so, the slow compound scan was increasingly superseded by fast (real-time) B-mode scanning, which replaced it completely by about 1980. As early as 1965, R. Soldner of the Siemens company[7] had developed the Vidoson 635 as the first mechanical fast B-mode scanner. This device was widely used starting in 1970 and became especially popular in internal medicine and obstetrics. An electronic linear-array scanner was produced by ADR in 1974. By 1980 at the latest, all major ultrasound companies had developed mechanical or electronic real-time scanners. Real-time B-mode imaging was the technical prerequisite for the increasingly rapid implementation of diagnostic ultrasound during this period.

Some more theoretically oriented scientists believed that technical advances in ultrasonography would make it possible to discriminate among different tissue types, thus enabling a reliable benign–malignant differentiation. As a result, "tissue characterization" became a key topic of discussion at international conferences, which were now being held at regular intervals. Meanwhile, further technical advances in ultrasound-guided biopsy were pursued initially at centers of diagnostic ultrasound.

Clinical ultrasound specialists favored that modality as a simple, low-risk method for establishing a morphologic diagnosis. Hans Henrick Holm stated this viewpoint succinctly in his book, *Interventional Ultrasound*[8]:
When considering the difficulties frequently encountered with conventional microscopy, it does not seem likely that tissue characterization with ultrasound or with any other imaging modality will make it possible, with clinically acceptable accuracy, e.g. routinely to distinguish between a benign and a malignant intra-abdominal lesion.

1.2.2 Technical Evolution of Ultrasound-Guided Biopsies

From a technical standpoint, Kratochwil's concept of using a single transducer with a central aperture on a compound scanner was easily moved from the design stage to practical reality (▶ Fig. 1.3). Biopsy transducers for compound scanners became available commercially only a short time after the Vienna Congress.[9,10] These devices were used in many early studies.

On the other hand, this technique was still somewhat laborious for percutaneous biopsies: First, an image of the intended target was acquired slowly with a bistable compound scanner (this took at least several seconds), and the image was stored in memory. After the desired puncture site had been marked on the skin, a sterilized biopsy transducer was fastened to the scanner arm and applied to the marked skin site. Next, the biopsy transducer was swept through a sector arc to redefine the desired plane. The only orientation guide available beyond this point was the static (frozen) B-mode image. The target and needle path could be directly observed during the biopsy itself only by viewing an A-mode display (▶ Fig. 1.4).

Needle insertion with the fast B-mode Vidoson system was done using freehand technique: The intended target was first defined in the B-mode image. The most favorable entry site in the second plane was located and marked on the skin by noting the acoustic shadow cast by a small wooden stick placed between the skin and transducer (▶ Fig. 1.5). The depth from skin to target was measured on the monitor screen and could be preset on the needle with a set screw. Whenever possible, the cumbersome (transducer placed in a water bag!) Vidoson was positioned next to the entry site so that the intended target and needle could be monitored directly in the B-mode image.[11] Other authors used a needle guide mounted on the side of the Vidoson. This design was available as a prototype developed by Siemens in about 1974,[12] or users could create their own homemade version[13] (▶ Fig. 1.6).

This principle was adopted in the easier-to-use handy sector scanners (with direct contact to the skin) that were developed later. In 1978, Saitoh and Watanabe worked with the Aloka company to develop an adapter for a sector scanner (▶ Fig. 1.7),[14] which was then marketed commercially. At about the same time, Kretz Ultrasound also developed an adapter for their Combison 100, which was widely used in Europe at that time.

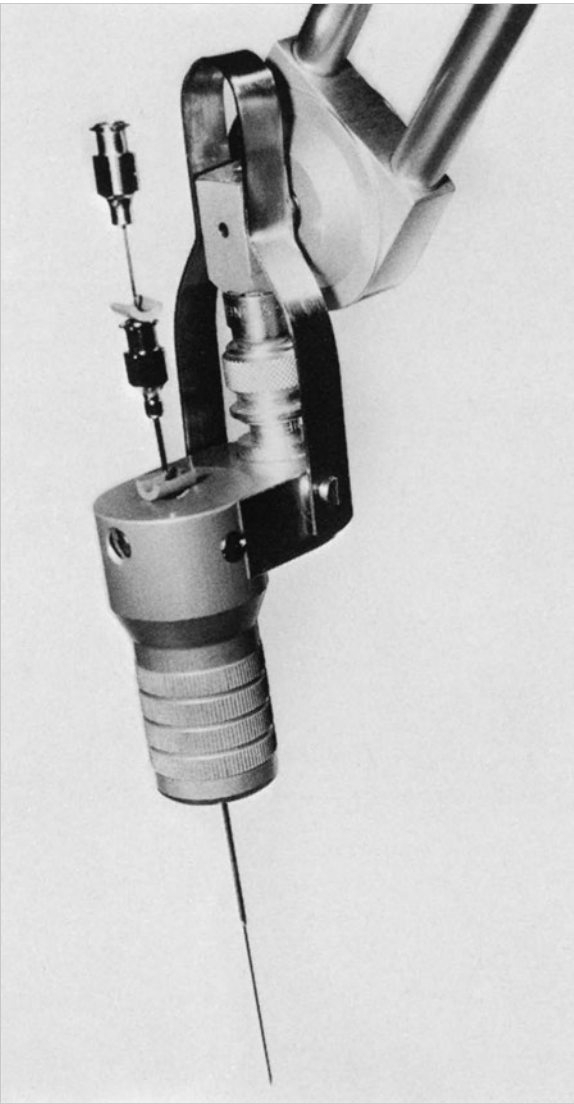

Fig. 1.3 Commercially available biopsy transducer (A-scan) with a central needle aperture, mounted on a compound scanner arm circa 1972.

A relatively simple, homemade linear array transducer with a central aperture (▶ Fig. 1.8) was first used by H. H. Holm in 1974 for applications such as amniocentesis. Under favorable conditions, the needle could be identified in the image. In 1976, Pedersen introduced the alternative design of a linear array device with a side-mounted needle guide,[15] which featured an adjustable needle angle (▶ Fig. 1.9). In 1980 Toshiba developed a special biopsy transducer with a triangular needle channel (▶ Fig. 1.10) for its SAL 20 linear array scanner. The

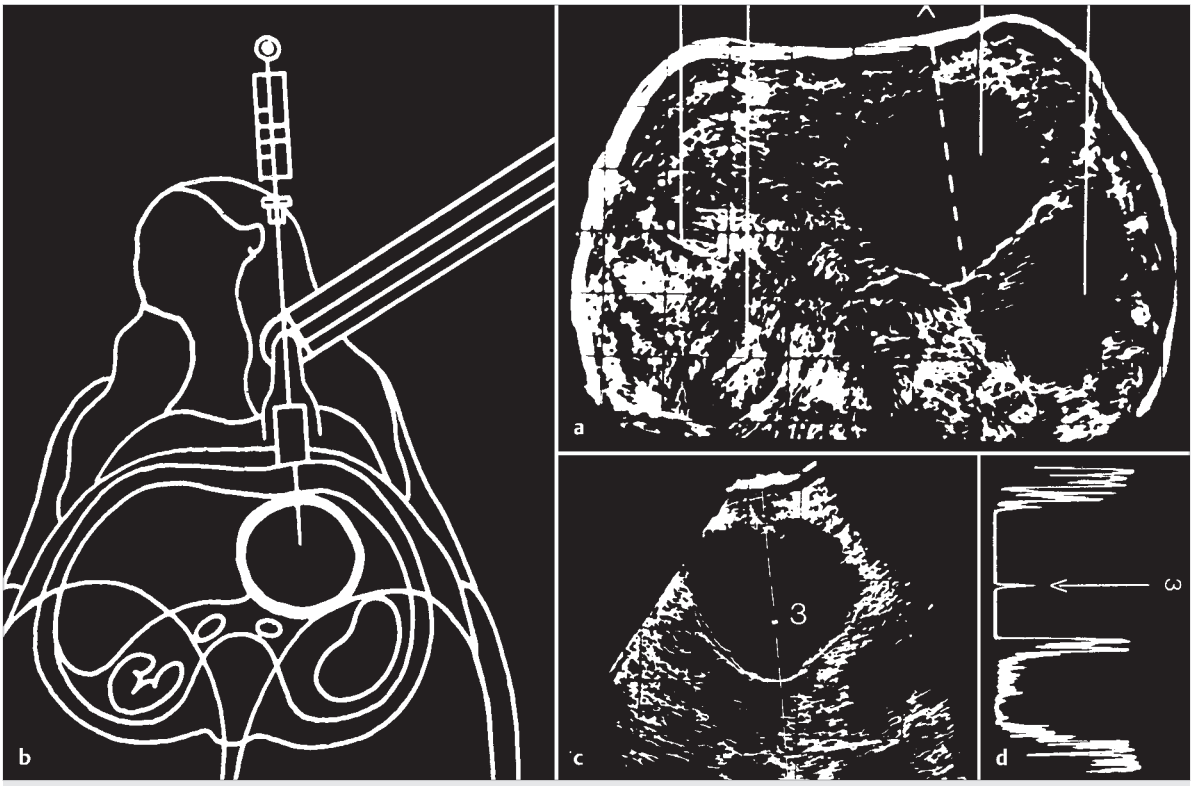

Fig. 1.4 Biopsy technique with a compound scanner.
a The intended target is displayed on a storage cathode-ray tube with a slow B-mode scan.
b The transducer is replaced with a (sterile) biopsy transducer (schematic illustration) (▶ Fig. 1.3).
c The intended target is again visualized in a sector-shaped scan (3 = needle tip).
d Direct observation of the biopsy needle in A-mode (← signal of the needle tip).

channel was open on one side for introducing the needle guide and needle and allowed the needle to be inserted at an oblique angle to the ultrasound beam.[16] This principle was advanced further by the development of disposable, plastic needle guides. The transducer could be placed within a sterile sheath and the sterile needle guide could be introduced from the side. In both systems, the needle path predefined by the needle guide was displayed in the image as an electronic line (▶ Fig. 1.11).

As special biopsy transducers were being developed and used, many examiners continued to use freehand technique for percutaneous biopsies (and many still do so today). This was facilitated by the development of smaller, lighter transducers that could be placed next to the puncture site. The needle could be observed as clearly as with a side-mounted adapter.[17] Freehand technique also simplified hygiene (transducers did not always have to be sterilized or placed in a sterile wrapper), and it was often possible to use shorter, less expensive needles.

Initially, material for cytologic analysis was aspirated from solid tumors with thin (≤ 0.7 mm), flexible Chiba-type needles using the technique described by Franzen.[18] A special syringe holder (Cameco, Sweden) was often used that allowed aspirations to be performed with one hand. Scandinavian authors in particular reported positive early experience with the cytologic analysis of well-preserved aspirated cells.[19–22] The basic equivalence between aspiration cytology and histologic biopsy had already been demonstrated in earlier studies, such as the study on liver biopsies published by Sheila Sherlock in 1967.[23] Later comparative studies confirmed these initial results, even showing a slight superiority of aspiration cytology with regard to the rate of nondiagnostic biopsies, for example.[24]

As the ultrasound-guided aspiration of solid tumors became more widely practiced, there was also a growing desire to obtain thin-needle core tissue samples for histologic examination. This desire arose mainly from pathologists, who generally preferred to work with histologic material or at least found it easier to identify malignant tumor types from histologic samples. Isler et al subsequently introduced a 22 gauge cutting needle in 1981.[25] The following year a commercially available modification of the Menghini needle called the Surecut needle[26] came into widespread use. The cutting edge at the needle tip excises a tissue core that is retained in the needle lumen by aspiration. Later the Trucut needle was also widely used. This needle slices off the tissue specimen in a side

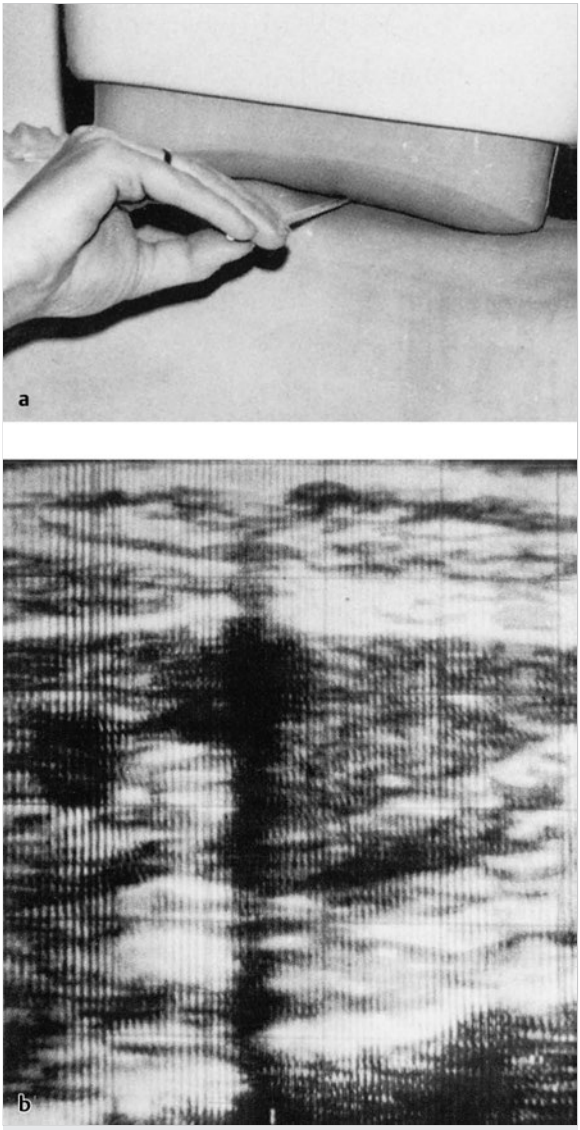

Fig. 1.5 Needle guidance with fast B-mode ultrasound (Siemens Vidoson). A small wooden stick placed between the transducer and skin (**a**) casts an acoustic shadow (**b**), which provides orientation in the second plane. The depth from skin to target is measured in the image. (Source: With kind permission from Springer Science + Business Media B.V.[77])

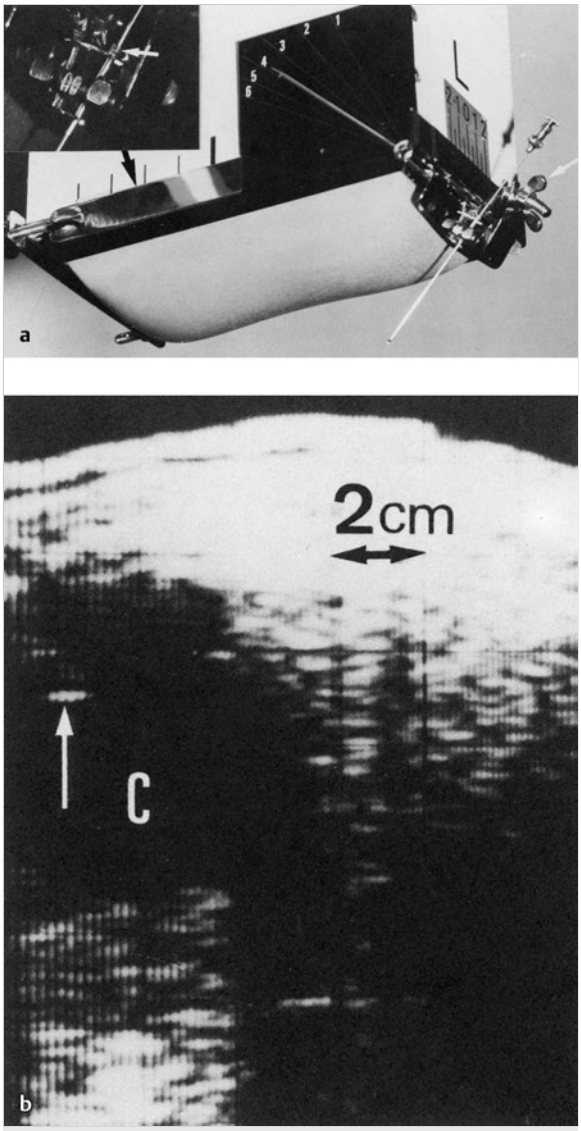

Fig. 1.6
a Vidoson (fast B-mode) with needle guide.
b Needle echo in a renal cyst (↑). (Source: Presented by Afschrift at the World Congress of Ultrasound in San Francisco in 1975. With kind permission from Springer Science + Business Media B.V.[13])

notch, allowing the tissue core to be removed within a sealed chamber. Cutting-needle biopsy was facilitated by the subsequent development of biopsy guns. These spring-loaded devices have an automated cutting action and are set to a specified biopsy depth before firing.

It could be difficult to detect the needle tip in the tissue, especially when a liner-array scanner was used. The ultrasound pulse travels parallel to the needle shaft and is not backscattered by the smooth needle surface, resulting in the absence of a definite tip echo on the screen. This prompted the development of special needles with transverse grooves at the tip. These grooves cause considerable (back)scattering of the sound, analogous to the reflector on a bicycle, giving rise to conspicuous echoes. But these needles were relatively expensive and more traumatizing than needles with a smooth surface. Examiners with good mechanical skills could score the needle tip themselves with a small file, producing a similar effect. Needles with a plastic sheath had better echogenicity but created a higher (frictional) resistance during insertion. Heckemann reported the results of comparative studies on the detectability of different needles in 1982.[27]



Fig. 1.7 Transducer with side-mounted needle holder and guide manufactured by Aloka. Developed in Japan by Saitho in 1978.[14]



Fig. 1.8 Simple electronic linear array scanner with a central aperture for a biopsy needle, "homemade" in the ultrasound laboratory at Gentofte Hospital (H. H. Holm; first used in 1974).

1.2.3 Clinical Application

The clinical application of ultrasound-guided percutaneous biopsies preceded technical developments. In other words, the rapid acceptance and implementation of this simple diagnostic (initially!) technique stimulated the development of special needles, guides, and biopsy transducers, not the other way around. Meanwhile, the expansion of ultrasound-guided biopsies to ever new and smaller target sites was dependent on advances in image quality, i.e., improvements in the resolution of ultrasound scanners.

At first, the organs of greatest interest were the liver and kidneys. Starting in 1972, initial studies based on small case numbers already revealed benefits from the ultrasound-guided fine needle biopsy of suspicious hepatic lesions, with a rate of nondiagnostic biopsies up to 10% and no false-positive results or serious complications.[11,28] Kristensen et al[29] reported on the fine needle biopsy of solid renal tumors in 1972, and Goldberg[30] described the diagnostic aspiration of renal cysts in 1973.

In 1974, Pedersen[31] reported on the ultrasound-guided percutaneous puncture of the (obstructed) renal pelvis for cytologic and microbiologic analysis as well as antegrade pyelography and nephrostomy (▶ Fig. 1.11).

In 1975, Hancke[32] and Smith[33] reported on the fine needle biopsy of suspicious solid pancreatic lesions using a compound scanner with a biopsy transducer. In 1976, Hancke[34] additionally reported on the puncture of pancreatic pseudocysts, initially for diagnostic reasons. This was followed in 1977 by reports from Makuuchi on the puncture of the dilated pancreatic duct (▶ Fig. 1.12) and antegrade cholangiography, followed in each case by radiographic visualization of the duct system.[16,35] Finally, advances in ultrasound equipment and resolution led to scores of reports and case studies up until 1985 dealing with the ultrasound-guided needle biopsy of suspected neoplasms in all abdominal regions.

In the field of cardiology, Goldberg[36] performed the first ultrasound-guided percutaneous aspirations of the pericardial sac as early as 1972. He used the biopsy transducer of the compound scan system with A-mode imaging of pericardial effusions and TM-mode imaging of cardiac pulsations. The fine needle biopsy of peripheral lung lesions under real-time ultrasound guidance was described by Schwerk in 1982.[37]

Ultrasound-guided vascular access for angiographic studies was first attempted with Doppler probes in 1973.[38] Catheter placement in the subclavian vein or internal jugular vein under ultrasound guidance was described in 1975.[39] B-mode image quality was constantly improved and was recommended for vascular localization in later studies.[40]

Ultrasound guidance in obstetrics and gynecology was used primarily to improve the safety of amniocentesis,[41] as was reported at the Vienna Congress. The percutaneous biopsy of gynecologic tumors, on the other hand, was not advocated because of a lack of indications as well as concerns about the intraperitoneal seeding of

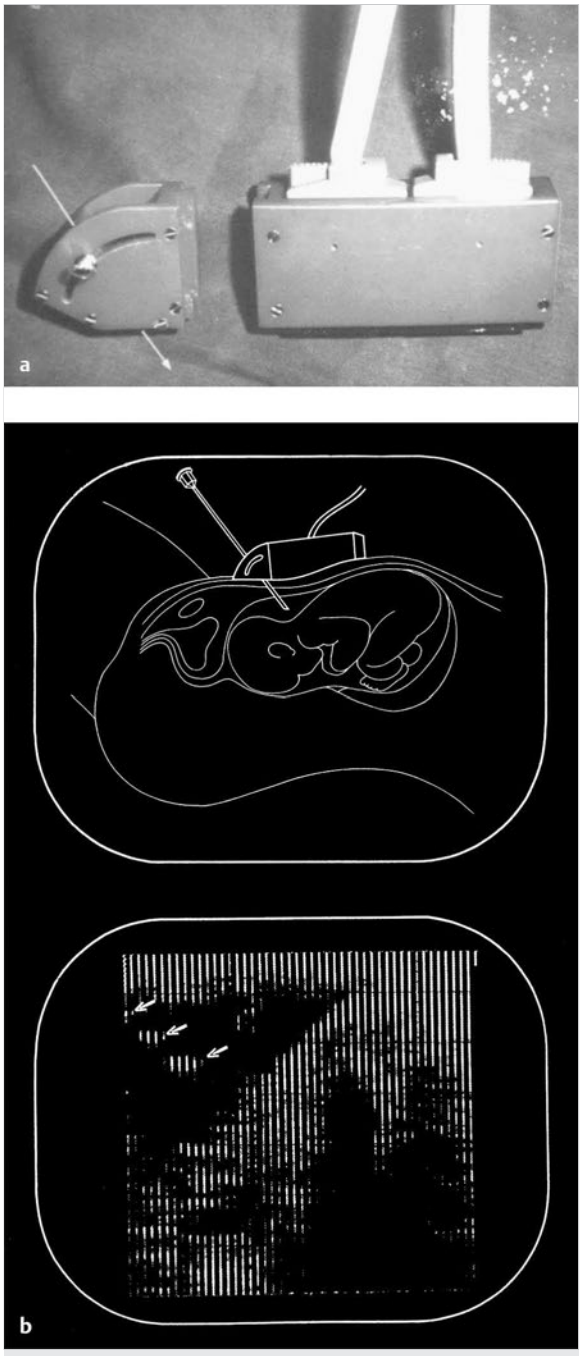

Fig. 1.9
a Electronic linear array scanner with side-mounted needle guide, "homemade" in the ultrasound laboratory at Gentofte Hospital.
b Original image obtained during amniocentesis, and corresponding drawing. The arrows indicate the needle echoes.

tumor cells. Needle biopsies were limited mainly to postoperative settings[42] such as the aspiration biopsy of suspicious retroperitoneal lymph nodes.[43] The ultrasound-guided biopsy of suspicious lesions in the breast was not introduced until after 1990.[44]

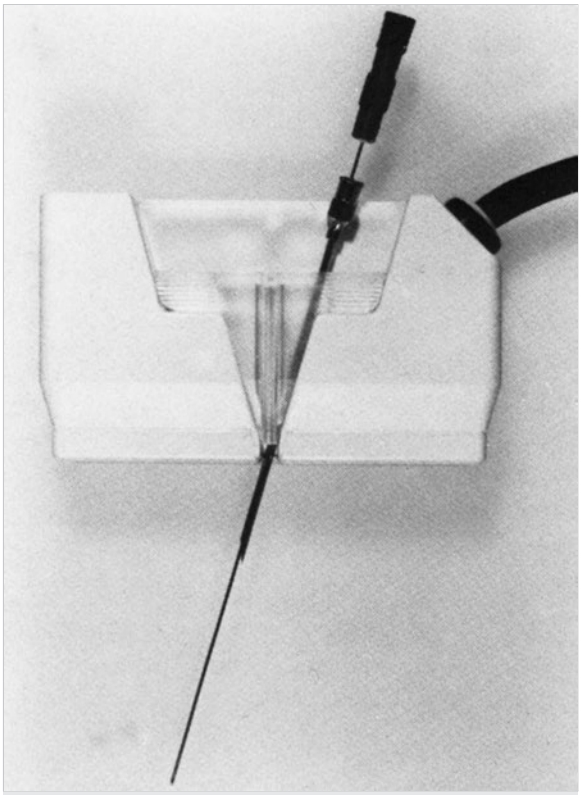

Fig. 1.10 Linear array transducer. Prototype of the Toshiba biopsy transducer made for the SAL 20, first available in 1978.

The "epicenter" at this stage in the development of interventional ultrasound was the ultrasound laboratory of Gentofte Hospital (later Herlev Hospital) in Copenhagen, Denmark, directed by H. H. Holm. Starting in 1978, this hospital began to host a series of international conferences on interventional ultrasound. Holm and Kristensen published their first book on ultrasound-guided

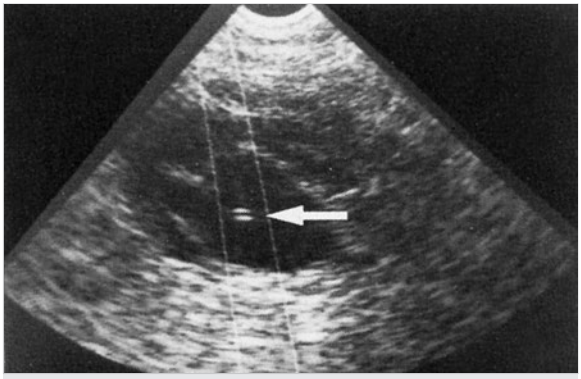

Fig. 1.11 Nephropyelostomy performed with a mechanical sector scanner and lateral needle guide. The needle path is marked electronically in the image. The needle tip (←) is clearly visible inside the cyst.

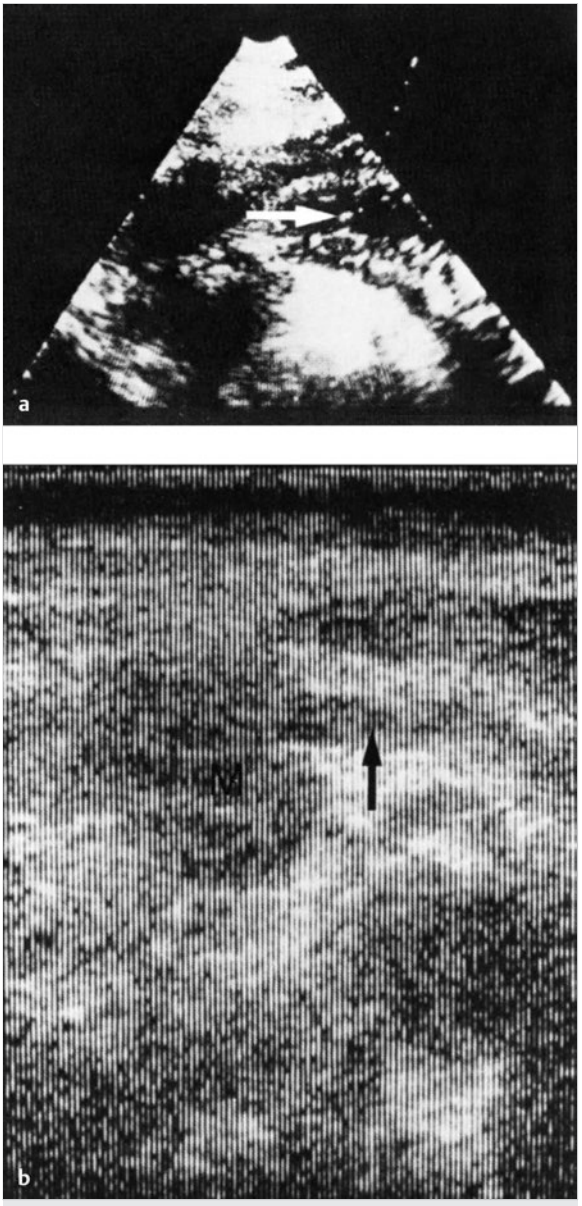

Fig. 1.12 Ultrasound-guided puncture of the dilated pancreatic duct in the presence of a pancreatic head tumor.
a Appearance of the needle tip in a compound scan.
b Real-time image with an electronic linear-array transducer (like that shown in ▶ Fig. 1.10). Note the discrepancy between equipment quality at that time and the availability of highly differentiated puncture techniques.

needle procedures in 1980. This was followed in 1985 by the book *Interventional Ultrasound*,[8] which reviews the development of interventional ultrasound during the 15 years after the Vienna Congress. This does not mean that important studies and discoveries were not made at many other centers and by many other clinicians. On the contrary, this branch of diagnostic ultrasound had what may be called a "multicentric" development. Interventional ultrasound was practiced very widely in German-speaking countries after about 1980, and some authors were able to report their experience in very large case numbers.[45] Ultrasound-guided needle biopsies were very often regarded as and performed as an integral component in the ultrasound investigation of suspected tumors, comparable to forceps biopsies in endoscopic examinations. It should be noted, however, that a biopsy turns a noninvasive ultrasound examination into an invasive procedure with associated risks that, while small, must still be taken into consideration.

1.2.4 Risks of Interventional Ultrasound

The risks of percutaneous biopsies were known and had been described in principle even before the age of interventional ultrasound.[46] Today they are still an important consideration in the development and practice of interventional sonography.

While initial studies showed no serious side effects associated with the use of needles less than 1 mm in diameter, publications over the years documented repeated instances of serious complications and even deaths, mostly in individual case reports.[47,48] Significant hemorrhages and bile leaks were described in association with liver biopsies, necrotizing pancreatitis after pancreatic biopsies, and the inadvertent transfer of infectious material leading to sepsis. Subsequent doctor surveys and reviews of the literature indicated a mortality rate between 0.001% and 0.096% with complication rates up to 0.9%.[47–52]

The risk of seeding tumor cells into the needle tract is a potentially serious problem. Reports of inoculation metastases from various tumors were published even before the era of ultrasound-guided biopsies.[47,48,50] As a precaution against needle-track seeding, Holm recommended introducing the actual biopsy needle through an outer needle that had been advanced to the biopsy site or target organ. A guide needle was also used for multiple sampling.[8] Holm believed that the Trucut needle was advantageous in this regard because it "sealed off" the tissue core prior to needle extraction. While some isolated case reports were published and analyzed in detail,[47] statistical data from very large case numbers indicated a risk of inoculation metastasis of less than 0.017%. Despite these low numbers, the debate on needle-tract seeding continued to be (and remains) controversial and emotionally charged. Grundmann was the first author, in 1979, to take a stand on this issue in the journal *Deutsches Ärzteblatt*,[53] and one year later the scientific advisory board of the Association of German Physicians issued a formal statement affirming that needle biopsies do not promote the spread of tumor cells.[54]

1.3 Later Developments: Ultrasound-Guided Therapeutic Interventional Procedures

By the mid-1980s, or about the time H. H. Holm published his book, ultrasound-guided needle biopsies had become an accepted and widely used method for establishing a rapid, definitive diagnosis at low risk.[8] New target sites were being added as the resolution of ultrasound images improved. The debate regarding cytologic versus histologic biopsy was continued in large clinical series,[55] with neither method showing a definite superiority. Discussions on the risk of needle-track seeding also continued.

Ambitious technical innovations such as superimposing a magnetic field over the B-mode image to allow "live" tracking of needle position or mounting an ultrasound transmitter on the needle tip were presented but were not widely adopted.

An important innovation, however, was the development of biopsy devices that could be used in conjunction with endosonography, which was being practiced on a growing scale. One of the first endosonographic techniques was transrectal imaging of the prostate. Ultrasound guidance enabled the prostate to be biopsied percutaneously by the transperitoneal route.[56] But flexible endoscopic ultrasound like that used in the digestive tract required biopsy needles that were integrated into the endoscope, and this technology was available by about 1990.

This later phase was marked by the development of therapeutic interventions, with Italian authors playing a leading role, especially in the treatment of solid tumors. In truth, therapeutic measures were already a part of interventional ultrasound from the beginning. For example, ultrasound-guided amniocentesis provided a safe means for performing intrauterine transfusions, first described by Hansmann in 1972,[57] using real-time imaging guidance. This in turn laid the groundwork for further advances in interventional intrauterine therapy.

From the outset, ultrasound-guided needles were used not only to detect and evaluate fluid collections but also, where necessary, to evacuate the fluid. Ultrasound guidance facilitated the percutaneous therapeutic aspiration of simple fluid collections such as ascites or pleural effusions and was sometimes an essential tool, as in cases complicated by adhesions. The "therapeutic" value of ultrasound guidance was already recognized during the early 1970s when applied to pericardiocentesis,[36] nephropyelotomy,[31] and the drainage of postoperative fluid collections such as lymphoceles.[58] Percutaneous cholangiography could also be followed by ultrasound-guided drainage if required.[35]

The diagnostic aspiration of intra-abdominal abscesses proved to be a low-risk procedure, like fine needle biopsies in general. It was a logical next step to evacuate and irrigate the abscess through the needle as a one-time procedure or to establish percutaneous catheter drainage, generally using Seldinger technique.[59–62] The biggest challenge circa 1974 lay in convincing surgical colleagues that these procedures were safe and effective.

In the early years of interventional ultrasound, the fine needle aspiration of cysts was still done for diagnostic reasons in selected cases to positively exclude a malignancy or confirm an abscess. Again, frequent efforts were also made to apply the procedure therapeutically. This was successfully accomplished in selected patients with pancreatic pseudocysts.[34] Often the pseudocysts still communicated with the duct system and tended to recur after evacuation. This led Hancke to develop a procedure for the internal gastric drainage of pancreatic pseudocysts by combining an ultrasound-guided percutaneous gastrostomy with gastroscopy. He published this technique in 1985.[63] At about the same time, a special percutaneous technique for the treatment of echinococcal cysts began to be developed in Tunisia and Italy.[64,65] After preliminary testing in sheep, the treatment, known by the acronym PAIR (puncture–aspiration–injection of alcohol–reaspiration), was finally incorporated into WHO guidelines for the treatment of cystic echinococcosis in 1996.[66]

Attempts to treat cysts definitively by a single aspiration were usually disappointing since a defining feature of cysts is the presence of a secretory epithelial lining. This suggested the idea of obliterating the epithelium with concentrated alcohol or other sclerosing agents. Reports on this treatment were first published in 1981 for renal cysts[67] and in 1989 for hepatic cysts.[68,69]

Solbiati reported in 1985 on the successful obliteration of enlarged parathyroid glands in secondary hyperparathyroidism by percutaneous ethanol injection (PEI).[70] This technique was later applied in the treatment of toxic thyroid nodules.[71,72]

Livraghi began to treat hepatocellular carcinomas and metastases by PEI in 1986[73] and by 1995 was able to report long-term results in 746 patients.[74] Buscarini and his group first reported on the percutaneous radiofrequency thermoablation (RFA) of liver tumors in 1991[75] and published long-term results in 2001.[76] Since that time, these treatment modalities have been adopted at many tumor centers and are also being tried on malignancies in other organs.

1.4 Outlook

The development of ultrasound-guided therapeutic interventions is not yet complete by any means. Positive experiences with guided needle placements for administering local anesthetics, as in carpal tunnel syndrome and other orthopedic problems, are but one example of this trend.

Fine needle aspirations and biopsies have become a well-established tool in the diagnostic armamentarium of

many specialties. The statement by H. H. Holm quoted earlier in this chapter is still true today. Even at its current level of quality, diagnostic ultrasound cannot replace a microscopic tissue analysis because an ultrasound image simply maps the acoustic properties of tissues. On the other hand, given the remarkable development of the modality itself, it may be possible in some cases to determine the malignant or benign nature of an organ lesion within the clinical context by close scrutiny of the B-mode image, a color Doppler assessment of vascular architecture, dynamic flow analysis with contrast-enhanced ultrasound, and tissue strain analysis by elastography. This approach may eliminate the need for an invasive puncture, despite its minimal risks, in growing numbers of patients. Today it is unclear whether and to what extent the guided application of micro bubbles targeted to specific markers can complement or even replace ultrasound-guided punctures.

References

[1] Kratochwil A, Lim-Rachmat F. Ultraschallplazentalokalisation. In: Böck J, Ossoinig K, eds. Ultrasonographia Medica. Vol. III. Vienna: Verlag der Wiener Medizinischen Akademie; 1969:275–284

[2] Blauenstein W, Engelhart GJ, Müller HR. Sonographie und stereotaktische Biopsie von Lebertumoren. In: Böck J, Ossoinig K, eds. Ultrasonographia Medica. Vol. III. Vienna: Verlag der Wiener Medizinischen Akademie; 1969:93–99

[3] Menghini G. One-second needle biopsy of the liver. Gastroenterology 1958; 35: 190–199

[4] Berlyne GM. Ultrasonics in renal biopsy: an aid to determination of kidney position. Lancet 1961; 2: 750–751 (preliminary communication)

[5] Rettenmaier G. Tiefenortung der Niere und Bestimmung der Parenchymstärke mit einem Ultraschall-schnittbildverfahren vor der perkutanen Nierenbiopsie. In: Otto P, ed. Fortschritte auf dem Gebiet der Röntgenstrahlen und der Nuklearmedizin. Stuttgart: Thieme; 1970:76–77

[6] Martin HE, Ellis EB. Biopsy by needle puncture and aspiration. Ann Surg 1930; 92: 169–181

[7] Krause W, Soldner R. Ultraschallbildverfahren (B-scan) mit hoher Bildfrequenz für medizinische Diagnostik. Electro-medica 1967; 4: 8–12

[8] Holm HH, Kristensen JK, eds. Interventional Ultrasound. Copenhagen: Munksgaard; 1985

[9] Goldberg BB, Pollack HM. Ultrasonic aspiration transducer. Radiology 1972; 102: 187–189

[10] Holm HH, Kristensen JK, Rasmussen SN, Northeved A, Barlebo H. Ultrasound as a guide in percutaneous puncture technique. Ultrasonics 1972; 10: 83–86

[11] Lutz H, Weidenhiller S, Rettenmaier G. Ultrasonically guided fine-needle biopsy of the liver [Article in German]. Schweiz Med Wochenschr 1973; 103: 1030–1033

[12] Soldner R. Personal communication

[13] Afschrift M, Colardyn F, Verdonk G. Ultrasonic guidance of percutaneous punctures by means of real time echography. In: White D, Brown RE, eds. Ultrasound in Medicine. 3rd ed. New York: Plenum; 1977:363–370

[14] Saitoh M, Watanabe H, Ohe H, Tanaka S, Itakura Y, Date S. Ultrasonic real-time guidance for percutaneous puncture. J Clin Ultrasound 1979; 7: 269–272

[15] Pedersen JF. Percutaneous puncture guided by ultrasonic multitransducer scanning. J Clin Ultrasound 1977; 5: 175–177

[16] Makuuchi M, Bandai Y, Ito T, Wada T. Ultrasonically guided percutaneous transhepatic cholangiography and percutaneous pancreatography. Radiology 1980; 134: 767–772

[17] Jakobeit C. Ultrasound-controlled puncture procedures: free-hand puncture versus transducer biopsy puncture. 5 years' experience [Article in German]. Ultraschall Med 1986; 7: 290–292

[18] Franzén S, Giertz G, Zajicek J. Cytological diagnosis of prostatic tumours by transrectal aspiration biopsy: a preliminary report. Br J Urol 1960; 32: 193–196

[19] Conn HO, Yesner R. A re-evaluation of needle biopsy in the diagnosis of metastatic cancer of the liver. Ann Intern Med 1963; 59: 53–61

[20] Esposti PL, Franzén S, Zajicek J. The aspiration biopsy smear. In: Koss G, ed. Diagnostic Cytology and Its Histopathologic Basis. 2nd ed. Philadelphia: JB Lippincott; 1968

[21] Lundquist A. Fine-needle aspiration biopsy for cytodiagnosis of malignant tumour in the liver. Acta Med Scand 1970; 188: 465–470

[22] Soderstrom N. Fine Needle Aspiration Biopsy. Orlando: Grune & Stratton; 1966

[23] Sherlock P, Kim YS, Koss LG. Cytologic diagnosis of cancer from aspirated material obtained at liver biopsy. Am J Dig Dis 1967; 12: 396–402

[24] Torp-Pedersen S, Vyberg M, Juul N, Sehested M. Fine needle histological sampling. In: Holm HH, Kristensen JK, eds. Interventional Ultrasound. Copenhagen: Munksgaard; 1985

[25] Isler RJ, Ferrucci JT, Jr, Wittenberg J et al. Tissue core biopsy of abdominal tumors with a 22 gauge cutting needle. AJR Am J Roentgenol 1981; 136: 725–728

[26] Torp-Pedersen S, Juul N, Vyberg M. Histological sampling with a 23 gauge modified Menghini needle. Br J Radiol 1984; 57: 151–154

[27] Heckemann R, Seidel KJ. In vitro and in vivo imaging of puncture instruments in the real-time ultrasound image. 1. Puncture needles [Article in German]. Ultraschall Med 1982; 3: 18–23

[28] Rasmussen SN, Holm HH, Kristensen JK, Barlebo H. Ultrasonically-guided liver biopsy. BMJ 1972; 2: 500–502

[29] Kristensen JK, Holm HH, Rasmussen SN, Barlebo H. Ultrasonically guided percutaneous puncture of renal masses. Scand J Urol Nephrol 1972; 6: 49–56

[30] Goldberg BB, Pollack HM. Ultrasonically guided renal cyst aspiration. J Urol 1973; 109: 5–7

[31] Pedersen JF. Percutaneous nephrostomy guided by ultrasound. J Urol 1974; 112: 157–159

[32] Hancke S, Holm HH, Koch F. Ultrasonically guided percutaneous fine needle biopsy of the pancreas. Surg Gynecol Obstet 1975; 140: 361–364

[33] Smith EH, Bartrum RJ, Jr, Chang YC et al. Percutaneous aspiration biopsy of the pancreas under ultrasonic guidance. N Engl J Med 1975; 292: 825–828

[34] Hancke S, Pedersen JF. Percutaneous puncture of pancreatic cysts guided by ultrasound. Surg Gynecol Obstet 1976; 142: 551–552

[35] Makuuchi M, Kamiya K, Beppu T. Percutaneous transhepatic cholangiography under ultrasonic guidance. Acta Hepat Jpn 1977; 18: 435–440

[36] Goldberg BB, Pollack HM. Ultrasonically guided pericardiocentesis. Am J Cardiol 1973; 31: 490–493

[37] Schwerk WB, Dombrowski H, Kalbfleisch H. Ultrasound tomography and guided fine needle biopsy of intrathoracic space occupying lesions [Article in German]. Ultraschall Med 1982; 3: 212–218

[38] Mozersky DJ, Olson RM, Coons HG, Hagood CO, Jr. Doppler-controlled needle director: a useful adjunct to angiography. Radiology 1973; 109: 221–222

[39] Petzoldt R, Kresse H. Punktion von Venen und Arterien mittels Ultraschall. Biomedizinische Technik 1975; 20: 345–346

[40] Metz S, Horrow JC, Balcar I. A controlled comparison of techniques for locating the internal jugular vein using ultrasonography. Anesth Analg 1984; 63: 673–679

[41] Bang J, Northeved A. A new ultrasonic method for transabdominal amniocentesis. Am J Obstet Gynecol 1972; 114: 599–601

[42] Jensen F. Puncture of gynecological masses. In: Holm HH, Kristensen JK, eds. Interventional Ultrasound. Copenhagen: Munksgaard; 1985

[43] Berkowitz RS, Leavitt T, Jr, Knapp RC. Ultrasound-directed percutaneous aspiration biopsy of periaortic lymph nodes in recurrence of cervical carcinoma. Am J Obstet Gynecol 1978; 131: 906–908
[44] Parker SH, Jobe WE, Dennis MA et al. US-guided automated large-core breast biopsy. Radiology 1993; 187: 507–511
[45] Otto R. Ultraschallgeführte Biopsie. Berlin: Springer; 1985
[46] Lindner H. Limitations and hazards of percutaneous liver biopsy with the Menghini needle. Experiences with 80,000 liver biopsies [Article in German]. Dtsch Med Wochenschr 1967; 92: 1751–1757
[47] Buscarini E, Di Stasi M. Complications of Abdominal Interventional Ultrasound. Milan: Poletto Edizione; 1996
[48] Smith EH. Fine-needle aspiration biopsy: are there any risks? In: Holm HH, Kristensen JK, eds. Copenhagen: Munksgaard; 1985
[49] Gebel M, Horstkotte H, Köster C, Brunkhorst R, Brandt M, Atay Z. Ultrasound-guided fine needle puncture of the abdominal organs: indications, results, risks [Article in German]. Ultraschall Med 1986; 7: 198–202
[50] Livraghi T, Damascelli B, Lombardi C, Spagnoli I. Risk in fine-needle abdominal biopsy. J Clin Ultrasound 1983; 11: 77–81
[51] Weiss H, Düntsch U, Weiss A. Risks of fine needle puncture—results of a survey in West Germany (German Society of Ultrasound in Medicine survey) [Article in German]. Ultraschall Med 1988; 9: 121–127
[52] Weiss H, Düntsch U. Complications of fine needle puncture. DEGUM survey II [Article in German]. Ultraschall Med 1996; 17: 118–130
[53] Grundmann E. Keine Metastasenförderung durch Biopsien. Dtsch Arzteblatt 1979; 7; 9: 699–702
[54] Wissenschaftlicher Beirat der Bundesärztekammer. Metastasenförderung durch diagnostische Gewebsentnahme (Biopsie)? Dtsch Arztebl 1980; 22: 1460–1467
[55] Buscarini L, Fornari F, Bolondi L et al. Ultrasound-guided fine-needle biopsy of focal liver lesions: techniques, diagnostic accuracy and complications. A retrospective study on 2091 biopsies. J Hepatol 1990; 11: 344–348
[56] Holm HH, Gammelgaard J. Ultrasonically guided precise needle placement in the prostate and the seminal vesicles. J Urol 1981; 125: 385–387
[57] Hansmann M, Lang N. Intrauterine transfusion controlled by ultrasound [Article in German]. Klin Wochenschr 1972; 50: 930–932
[58] Spigos D, Capek V. Ultrasonically guided percutaneous aspiration of lymphoceles following renal transplantation: a diagnostic and therapeutic method. J Clin Ultrasound 1976; 4: 45–46
[59] Braun B, Dormeyer HH. Ultrasonically guided fine needle aspiration biopsy of hepatic and pancreatic space-occupying lesions and percutaneous abscess drainage. Klin Wochenschr 1981; 59: 707–712
[60] Grønvall S, Gammelgaard J, Haubek A, Holm HH. Drainage of abdominal abscesses guided by sonography. AJR Am J Roentgenol 1982; 138: 527–529
[61] Smith EH, Bartrum RJ, Jr. Ultrasonically guided percutaneous aspiration of abscesses. Am J Roentgenol Radium Ther Nucl Med 1974; 122: 308–312
[62] vanSonnenberg E, Mueller PR, Ferrucci JT, Jr. Percutaneous drainage of 250 abdominal abscesses and fluid collections. Part I: Results, failures, and complications. Radiology 1984; 151: 337–341
[63] Hancke S, Henriksen FW. Percutaneous pancreatic cystogastrostomy guided by ultrasound scanning and gastroscopy. Br J Surg 1985; 72: 916–917
[64] Ben Amor N, Gargouri M, Gharbi HA, Golvan YJ, Ayachi K, Kchouck H. Trial therapy of inoperable abdominal hydatid cysts by puncture [Article in German]. Ann Parasitol Hum Comp 1986; 61: 689–692
[65] Filice C, Pirola F, Brunetti E, Dughetti S, Strosselli M, Foglieni CS. A new therapeutic approach for hydatid liver cysts. Aspiration and alcohol injection under sonographic guidance. Gastroenterology 1990; 98: 1366–1368
[66] WHO informal Working Group on Echinococcosis. Guidelines for treatment of cystic and alveolar echinococcosis in humans. Bull World Health Organ 1996; 74: 213–242
[67] Bean WJ. Renal cysts: treatment with alcohol. Radiology 1981; 138: 329–331
[68] Andersson R, Jeppsson B, Lunderquist A, Bengmark S. Alcohol sclerotherapy of non-parasitic cysts of the liver. Br J Surg 1989; 76: 254–255
[69] vanSonnenberg E, Wroblicka JT, D'Agostino HB et al. Symptomatic hepatic cysts: percutaneous drainage and sclerosis. Radiology 1994; 190: 387–392
[70] Solbiati L, Giangrande A, De Pra L, Bellotti E, Cantù P, Ravetto C. Percutaneous ethanol injection of parathyroid tumors under US guidance: treatment for secondary hyperparathyroidism. Radiology 1985; 155: 607–610
[71] Braun B, Blank W. Color Doppler sonography-guided percutaneous alcohol instillation in the therapy of functionally autonomous thyroid nodules [Article in German]. Dtsch Med Wochenschr 1994; 119: 1607–1612
[72] Livraghi T, Paracchi A, Ferrari C et al. Treatment of autonomous thyroid nodules with percutaneous ethanol injection: preliminary results. Work in progress. Radiology 1990; 175: 827–829
[73] Livraghi T, Festi D, Monti F, Salmi A, Vettori C. US-guided percutaneous alcohol injection of small hepatic and abdominal tumors. Radiology 1986; 161: 309–312
[74] Livraghi T, Giorgio A, Marin G et al. Hepatocellular carcinoma and cirrhosis in 746 patients: long-term results of percutaneous ethanol injection. Radiology 1995; 197: 101–108
[75] Buscarini L, Fornari F. Rossi P. Interstitial radiofrequency hyperthermia in the treatment of small hepatocellular carcinoma: percutaneous sonography-guidance of electrode needle. In: Anderegg A, Despland PA, Otto R, Henner H, eds. Ultraschall Diagnostik 1992;91:218–222
[76] Buscarini L, Buscarini E, Di Stasi M, Vallisa D, Quaretti P, Rocca A. Percutaneous radiofrequency ablation of small hepatocellular carcinoma: long-term results. Eur Radiol 2001; 11: 914–921
[77] Lutz H. Ultraschalldiagnostik (B-scan) in der Inneren Medizin. Berlin, Heidelberg, New York: Springer; 1978

2 Interventional Materials and Equipment

2.1 General Considerations on Interventional Procedures

U. Gottschalk, C. F. Dietrich

2.1.1 Brief Historical Introduction

Ultrasound-guided interventional procedures may be performed for diagnostic as well as therapeutic reasons. The goal of diagnostic procedures is to collect tissue or fluid samples for analysis, using percutaneous needles of various sizes and designs. One drawback of using large-caliber needle systems was already noted in an article published over 60 years ago[1]: "When we consider that percutaneous drainage rates need to be limited, it is pointless to use very large needles or trocars since the outflow must often be interrupted by clamping the tube so that fluid is not evacuated too rapidly." In the age before adequate imaging techniques were available, necessary drain size could usually be determined only by percutaneous aspiration, prompting an early policy statement that percutaneous drainage should never be attempted without prior needle aspiration.[2] An empyema, for example, required the placement of a drain approximately 15 to 20 mm in diameter. Milestones in the development of biopsy techniques are summarized in ▶ Table 2.1.

2.1.2 Biopsy Principles and Techniques

Freehand Biopsy, Needle Guide Attachments, and Biopsy Transducers

The most widely practiced ultrasound-guided biopsy techniques are a "blind" biopsy performed at a marked skin site after ultrasound localization, the freehand technique with one hand holding the transducer and the other guiding the needle, and the use of a needle guide or special biopsy transducer (▶ Table 2.2).

In the freehand technique, the needle is guided freely by the operator's hand. The challenge is to keep the needle at a proper angle to the imaging plane so that it is visible at all times. The main advantage of this technique is its flexibility. This makes it easier, for example, to interpose a

Table 2.1 Milestones in the development of biopsy techniques

Year	Procedure	Localization	First describer	Source
1851	Percutaneous tumor biopsy	Palpation, percussion	Lebert	3
1853	Breast tumor biopsy	Palpation, percussion	Paget	4
1883	Lung biopsy, identify infecting organism in pneumonia	Palpation, percussion	Leyerden	5
1883	Liver biopsy	Palpation, percussion	Ehrlich	6,7
1925	Special technique for fine needle biopsy	Palpation, percussion	Martin, Ellis	8
1930/1931	Bone marrow aspiration and biopsy	Palpation, percussion	Martin, Coley	9
1935	Vertebral body needle biopsy	Palpation, percussion	Robertson, Ball	10
1939	Lung tumor biopsy	Radiography	Blady	11
1951	Percutaneous pancreatic biopsy	Radiography	Kistland	12
1952	Thyroid biopsy	Palpation	Söderström	13
1952	Percutaneous renal biopsy	Radiography	Lindblom	14
1958	One-second liver biopsy	Percussion	Menghini	15
1967/1977	Lymph node biopsy, transperitoneal	Radiographic guidance	Nordenström, Zornoza	16
1972	Percutaneous liver biopsy	Ultrasound	Rasmusen	14
1975	Percutaneous pancreatic biopsy	Ultrasound	Hancke	16