# EPILEPSY

## The Intersection of Neurosciences, Biology, Mathematics, Engineering, and Physics

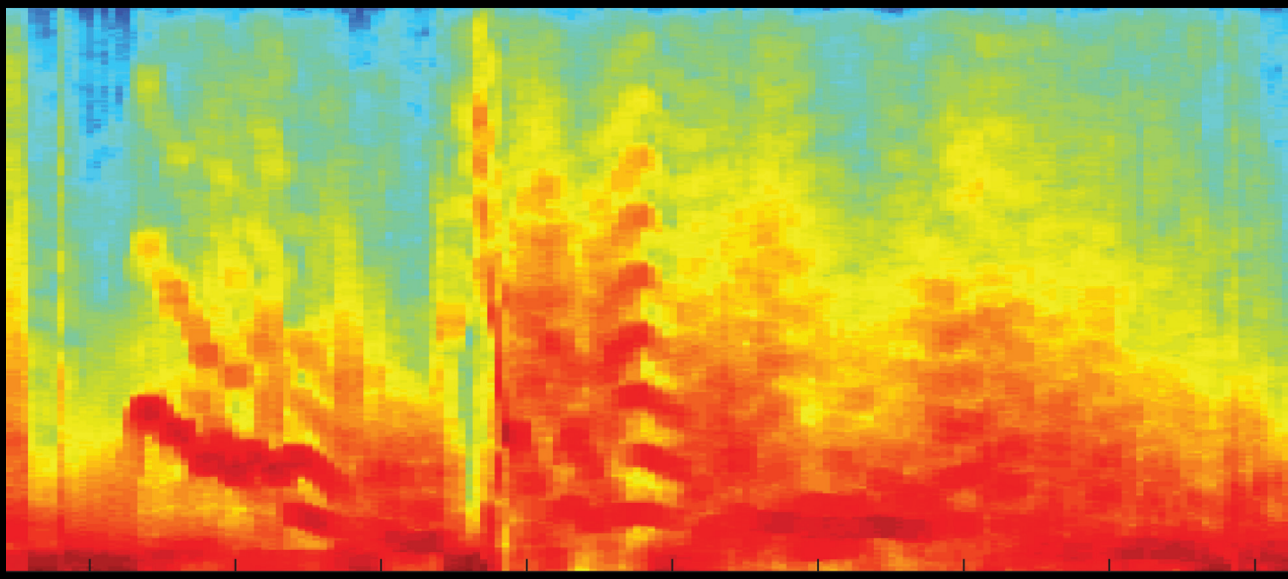

EDITED BY

Ivan Osorio • Hitten P. Zaveri

Mark G. Frei • Susan Arthurs

CRC Press

Taylor & Francis Group

# EPILEPSY

## The Intersection of Neurosciences, Biology, Mathematics, Engineering, and Physics

# EPILEPSY

## The Intersection of Neurosciences, Biology, Mathematics, Engineering, and Physics

EDITED BY
Ivan Osorio • Hitten P. Zaveri
Mark G. Frei • Susan Arthurs

CRC Press
Taylor & Francis Group
Boca Raton London New York

CRC Press is an imprint of the
Taylor & Francis Group, an **informa** business

CRC Press
Taylor & Francis Group
6000 Broken Sound Parkway NW, Suite 300
Boca Raton, FL 33487-2742


CRC Press is an imprint of Taylor & Francis Group, an Informa business



Printed in the United States of America on acid-free paper
10 9 8 7 6 5 4 3 2 1

International Standard Book Number-13: 978-1-4398-3886-0 (Ebook-PDF)



**Visit the Taylor & Francis Web site at**
**http://www.taylorandfrancis.com**

**and the CRC Press Web site at**
**http://www.crcpress.com**

*This book is dedicated to all epilepsy patients and their caregivers who carry the burden of this disease and for whom we work to provide better treatments. We also acknowledge all of the researchers from the many disciplines and from around the world who tirelessly focus on epilepsy in general and seizure prediction in particular.*

# Contents

Preface ..... xi
Acknowledgments ..... xiii
Editors ..... xv
Contributors ..... xvii

## SECTION I Foundations of Epilepsy

**Chapter 1** Neuroanatomy as Applicable to Epilepsy: Gross and Microscopic Anatomy/Histology ..... 3
*Taufik A. Valiante*

**Chapter 2** Introduction to EEG for Nonepileptologists Working in Seizure Prediction and Dynamics ..... 23
*Richard Wennberg*

**Chapter 3** Basic Mechanisms of Seizure Generation ..... 41
*John G. R. Jefferys and Premysl Jiruska*

**Chapter 4** An Introduction to Epileptiform Activities and Seizure Patterns Obtained by Scalp and Invasive EEG Recordings ..... 51
*Andreas Schulze-Bonhage*

**Chapter 5** Seizures and Epilepsy: An Overview ..... 65
*Steven Weinstein*

## SECTION II Foundations of Engineering, Math, and Physics

**Chapter 6** Intracranial EEG: Electrodes, Filtering, Amplification, Digitization, Storage, and Display ..... 81
*Hitten P. Zaveri and Mark G. Frei*

**Chapter 7** Time-Frequency Energy Analysis ..... 95
*Piotr J. Franaszczuk*

**Chapter 8** Neurodynamics and Ion Channels: A Tutorial ..... 111
*John G. Milton*

**Chapter 9** Nonlinear Time Series Analysis in a Nutshell ..... 125
*Ralph G. Andrzejak*

**Chapter 10** How to Detect and Quantify Epileptic Seizures ..... 139
*Sridhar Sunderam*

**Chapter 11** Automated Prediction and Assessment of Seizure Prediction Algorithms..... 165
*Florian Mormann, Ralph G. Andrzejak, and Klaus Lehnertz*

**Chapter 12** Autonomous State Transitions in the Epileptic Brain: Anticipation and Control .... 175
*Stiliyan N. Kalitzin, Demetrios N. Velis, and Fernando Lopes da Silva*

## *SECTION III The Challenge of Prediction*

**Chapter 13** Prediction ..... 203
*Didier Sornette and Ivan Osorio*

## *SECTION IV The State of Seizure Prediction: Seizure Prediction and Detection*

**Chapter 14** Impact of Biases in the False-Positive Rate on Null Hypothesis Testing ..... 241
*Ralph G. Andrzejak, Daniel Chicharro, and Florian Mormann*

**Chapter 15** Seizure Prediction: An Approach Using Probabilistic Forecasting ..... 249
*Bjoern Schelter, Hinnerk Feldwisch-Drentrup, Andreas Schulze-Bonhage, and Jens Timmer*

**Chapter 16** Seizure Prediction and Detection Research at Optima Neuroscience ..... 257
*Deng-Shan Shiau, Jui-Hong Chien, Ryan T. Kern, Panos M. Pardalos, and J. Chris Sackellares*

**Chapter 17** Preictal Directed Interactions in Epileptic Brain Networks ..... 265
*Klaus Lehnertz, Dieter Krug, Matthäus Staniek, Dennis Glüsenkamp, and Christian E. Elger*

**Chapter 18** Seizure Prediction and Observability of EEG Sources..... 273
*Elma O'Sullivan-Greene, Levin Kuhlmann, Andrea Varsavsky, David B. Grayden, Anthony N. Burkitt, and Iven M. Y. Mareels*

**Chapter 19** Circadian Regulation of Neural Excitability in Temporal Lobe Epilepsy ..... 289

*Paul R. Carney, Sachin S. Talathi, Dong-Uk Hwang, and William Ditto*

**Chapter 20** Use of Dynamical Measures in Prediction and Control of Focal and Generalized Epilepsy ..... 307

*Shivkumar Sabesan, Leon Iasemidis, Konstantinos Tsakalis, David M. Treiman, and Joseph Sirven*

**Chapter 21** Time-Series-Based Real-Time Seizure Prediction ..... 321

*Pooja Rajdev and Pedro P. Irazoqui*

**Chapter 22** Optimizing Seizure Detection Algorithms toward the Development of Implantable Epilepsy Prostheses ..... 331

*Shriram Raghunathan and Pedro P. Irazoqui*

**Chapter 23** Initiation and Termination of Seizure-Like Activity in Small-World Neural Networks ..... 341

*Alexander Rothkegel, Christian E. Elger, and Klaus Lehnertz*

**Chapter 24** Are Interaction Clusters in Epileptic Networks Predictive of Seizures? ..... 349

*Stephan Bialonski, Christian E. Elger, and Klaus Lehnertz*

**Chapter 25** Preictal Spikes in the Hippocampus of Patients with Mesial Temporal Lobe Epilepsy ..... 357

*C. Alvarado-Rojas, M. Valderrama, G. Huberfeld, and M. Le Van Quyen*

## *SECTION V The State of Seizure Prediction: Seizure Generation*

**Chapter 26** Microanalysis and Macroanalysis of High-Frequency Oscillations in the Human Brain ..... 369

*B. Crépon, M. Valderrama, C. Alvarado-Rojas, V. Navarro, and M. Le Van Quyen*

## *SECTION VI The State of Seizure Prediction: Seizure Control*

**Chapter 27** Vagus Nerve Stimulation Triggered by Machine Learning–Based Seizure Detection: Initial Implementation and Evaluation ..... 385

*Ali Shoeb, Trudy Pang, John V. Guttag, and Steven C. Schachter*

**Chapter 28** Low-Frequency Stimulation as a Therapy for Epilepsy ..... 397

*Jeffrey H. Goodman*

## SECTION VII The State of Seizure Prediction: Technology

**Chapter 29** Large-Scale Electrophysiology: Acquisition, Storage, and Analysis ..... 409

*Matt Stead, Mark R. Bower, Benjamin H. Brinkmann, Christopher Warren, and Gregory A. Worrell*

**Chapter 30** EPILAB: A MATLAB® Platform for Multifeature and Multialgorithm Seizure Prediction ..... 417

*B. Direito, R. P. Costa, H. Feldwisch-Drentrup, M. Valderrama, S. Nikolopoulos, B. Schelter, M. Jachan, C. A. Teixeira, L. Aires, J. Timmer, M. Le Van Quyen, and A. Dourado*

**Chapter 31** Emerging Technologies for Brain-Implantable Devices ..... 429

*Bruce Lanning, Bharat S. Joshi, Themis R. Kyriakides, Dennis D. Spencer, and Hitten P. Zaveri*

## SECTION VIII Nocturnal Frontal Lobe Epilepsy: A Paradigm for Seizure Prediction?

**Chapter 32** Familial and Sporadic Nocturnal Frontal Lobe Epilepsy (NFLE)—Electroclinical Features ..... 445

*Gholam K. Motamedi and Ronald P. Lesser*

**Chapter 33** Nicotinic Acetylcholine Receptors in Circuit Excitability and Epilepsy: The Many Faces of Nocturnal Frontal Lobe Epilepsy ..... 451

*Ortrud K. Steinlein and Daniel Bertrand*

**Chapter 34** Channelopathies in Epileptology ..... 461

*Frank Lehmann-Horn, Yvonne Weber, Snezana Maljevic, Karin Jurkat-Rott, and Holger Lerche*

**Chapter 35** Autosomal Dominant Nocturnal Frontal Lobe Epilepsy: Excessive Inhibition? ..... 469

*Molly N. Brown and Gregory C. Mathews*

**Chapter 36** How to Measure Circadian Rhythmicity in Humans ..... 477

*Wytske A. Hofstra and Al W. de Weerd*

**Chapter 37** Seizure Prediction and the Circadian Rhythm ..... 489

*Tyler S. Durazzo and Hitten P. Zaveri*

**Chapter 38** Nocturnal Frontal Lobe Epilepsy: Metastability in a Dynamic Disease? ..... 501

*John G. Milton, Austin R. Quan, and Ivan Osorio*

# Preface

*Epilepsy: The Intersection of Neurosciences, Biology, Mathematics, Engineering, and Physics* conflates the didactic sessions, keynote lectures, and scientific presentations delivered at the Fourth International Workshop on Seizure Prediction held in Kansas City, Missouri in the spring of 2009 and at the Sanibel Symposium (Nocturnal Frontal Lobe Epilepsy: An Interdisciplinary Perspective) convened on Sanibel Island, Florida in the winter of 2010. The complexity and diversity of the subject matter contained in this book coupled with the contributors' worthy efforts to meet the inherent challenge to make its contents accessible to researchers with disparate scientific backgrounds, makes this book a useful source for those outside the field as well those inside. Students of the dynamical behavior of seizures and those aspiring to predict their occurrence with a worthwhile degree of clinical utility and implement timely therapeutic interventions may be its greatest beneficiaries.

Of all neurological disorders, epilepsy demands of investigators the broadest and deepest knowledge of dynamical, control, and system theories, knowledge that cannot be amassed without possessing a certain level of sophistication in relevant areas of physics, mathematics, and engineering. A small but growing number of epileptologists realize that substantive progress in their field of endeavor will not materialize without transcending conventional approaches and the insularity of their efforts. Contributions from mathematicians, physicists, engineers, computer scientists, and other disciplines have been welcomed and are beginning to bear fruit. This book, albeit imperfectly, attempts to both capture and enrich the burgeoning interdisciplinary synergism in the nascent field of dynamical epileptology by narrowing the inescapable cultural chasm that commonly fragments multidisciplinary efforts. To address this innate risk, the meetings and the book's contents have been organized around five themes: 1. Foundations of Epilepsy (Chapters 1–5) introduces nonphysicians to language and concepts necessary to establish a meaningful dialog with epileptologists; 2. Foundations of Engineering, Math, and Physics (Chapters 6–12) expands the fund of knowledge of physicians into areas such as dynamical theory and signal processing without which the synthesis of concepts and ideas into testable hypotheses would be onerous and likely barren; 3. Challenge of Prediction (Chapter 13) delves into the issue of how to assess the degree of predictability from a system's behavior and the techniques required for fulfillment of this aim, by mining of knowledge from fields devoted to the investigation of aperiodic paroxysmal phenomena, such as earthquakes, so as to lay the proper foundations for dynamical epileptology and foster much needed growth efficiently; 4. The State of Seizure Prediction, Generation and Control (Chapters 14–31) provides an update of advancements in our understanding of the spatiotemporal behavior of seizures and of the mechanisms of epileptogenesis and ictogenesis as well as of seizure control and ancillary technology; and 5. Nocturnal Frontal Lobe Epilepsy: A Paradigm for Seizure Prediction? (Chapters 32–38) calls attention to an ignored syndrome, nocturnal frontal lobe epilepsy, whose proclivity for seizures to occur during a certain sleep stage may facilitate the task of identifying a precursory state, if existent, while markedly narrowing the search space.

The editors recognize and express their gratitude to those who generously put to pen their insights into a spinous but intellectually stimulating field of study and to the federal and private organizations and individuals* that provided the means to foster coalescence of seemingly disparate topics, concepts, and viewpoints into printed matter.

* See Acknowledgments for a complete list of sponsors.

MATLAB® is a registered trademark of The MathWorks, Inc. For product information, please contact:

The MathWorks, Inc.
3 Apple Hill Drive
Natick, MA 01760-2098 USA
Tel: 508-647-7000
Fax: 508-647-7001
E-mail: info@mathworks.com
Web: www.mathworks.com

# Acknowledgments

Funding for Fourth International Workshop on Seizure Prediction and the Sanibel Symposium (Nocturnal Frontal Lobe Epilepsy: An Interdisciplinary Perspective) was provided by the following government agencies, foundations, companies, university and hospital partners, and individuals: National Institutes of Health* (Grant No. R13NS065535 from the National Institute of Neurological Disorders and Stroke, Office of Rare Diseases Research and National Institute of Child Health and Human Development), Alliance for Epilepsy Research, UCB, Cyberonics, Deutsche Gesellschaft für Epileptologie, NeuroVista, American Epilepsy Society, CURE, University of Kansas Medical Center, Children's Mercy Hospitals and Clinics, Honeywell–Kansas City Plant, Ad-Tech, Cardinal Health, Medtronic, DIXI, Boulevard Brewing Co., and Mary Shaw Branton, Don Alexander, and Frank and Helen Wewers.

* The views expressed in this publication do not necessarily represent the official views of the National Institutes of Health, NINDS, ORDR, or NICHD and do not necessarily reflect the official policies of the Department of Health and Human Services; nor does mention by trade names, commercial practices, or organizations imply endorsement by the U.S. Government.

# Editors

**Ivan Osorio**— Ivan Osorio, a physician scientist and epileptologist, is professor of neurology at the University of Kansas Medical Center and the R. Adams Institute of Analytical Biochemistry. He is a Distinguished Visiting Neuroscience Professor at the Claremont Colleges' Joint Science Department and a visiting scholar at Harvey Mudd's Department of Mathematics. He serves on the editorial boards of several journals and on NINDS' study sections.

His research interests are the characterization of the spatiotemporal behavior of seizures, the development of intelligent devices for automated seizure detection, warning, and control, quantitative real-time assessment of therapeutic efficacy and real-time optimization, and the application of control and systems theory to the study and treatment of epilepsy.

**Hitten Zaveri**—Hitten P. Zaveri is an associate research scientist in the Department of Neurology at Yale University. Dr. Zaveri has received academic training in electrical engineering (BSE, MSE), computer engineering (BSE), and biomedical engineering (MS, PhD) from the University of Michigan in Ann Arbor and postdoctoral training in epilepsy and neurology from Yale University. He is the director of the Yale University Computational Neurophysiology Laboratory. His research interests lie at the intersection of neuroscience, engineering, and mathematics.

**Mark G. Frei**—Mark G. Frei is the managing director and technical director of Flint Hills Scientific, L.L.C. (FHS), a development stage research and development company in Lawrence, Kansas that Dr. Frei cofounded in 1995. He specializes in real-time quantitative analysis, filtering, identification and control of complex systems and signals, and in algorithm development for intelligent medical devices. He is an inventor on more than 30 patents, including several involving epileptic seizure detection. Prior to joining FHS, Dr. Frei was a postdoctoral fellow at the University of Kansas, in the Kansas Institute for Theoretical and Computational Science, the Comprehensive Epilepsy Center, and the Department of Mathematics. He received his PhD in mathematics from the University of Kansas with research specialties in the fields of modeling, prediction, and adaptive control of complex systems, and has authored or coauthored several scientific articles. He received his MS in applied mathematics/electrical engineering from the University of Southern California and BA in mathematics from the University of California Los Angeles. Prior to his doctoral training at the University of Kansas, Dr. Frei was a member of the technical staff of TRW, Inc.

**Susan Arthurs**—Susan Arthurs is a former United Airlines pilot who lost her career to epilepsy. In 1996, she cofounded the Alliance for Epilepsy Research, a 501(c)(3) charitable organization, and is currently executive director and secretary of the board. She is director and producer of the 2009 award-winning documentary, "It Is Epilepsy: The Challenges and Promises of Automated Seizure Control," which was created to increase public awareness of epilepsy and provide hope for those who have epilepsy in their lives. From 2000 to 2004, Susan was an adjunct instructor then assistant professor in the Department of Aviation at the University of Central Missouri. She also developed and is marketing the "Take Flight!" series of books with interactive CDs that contain ideas and resources for aviation and space activities for Grades K through 12. Susan has a BS degree from Penn State University in secondary mathematics education and a MS from the University of Central Missouri in aviation safety.

# Contributors

**L. Aires**
Faculty of Sciences and Technology
University of Coimbra
Coimbra, Portugal

**C. Alvarado-Rojas**
Centre de Recherche de l'Institut du Cerveau et de la Moelle épinière
Hôpital de la Pitié-Salpêtrière
Paris, France

**Ralph G. Andrzejak**
Department of Information and Communication Technology
Universitat Pompeu Fabra
Barcelona, Spain

**Daniel Bertrand**
Department of Neuroscience
Medical Faculty
University of Geneva
Geneva, Switzerland

**Stephan Bialonski**
Department of Epileptology
and
Helmholtz Institute for Radiation and Nuclear Physics
and
Interdisciplinary Center for Complex Systems
University of Bonn
Bonn, Germany

**Mark R. Bower**
Mayo Systems Electrophysiology Laboratory
Division of Epilepsy and Section of Electroencephalography
and
Department of Neurology
Mayo Clinic
Rochester, Minnesota

**Benjamin H. Brinkmann**
Mayo Systems Electrophysiology Laboratory
Division of Epilepsy and Section of Electroencephalography
and
Department of Neurology
Mayo Clinic
Rochester, Minnesota

**Molly N. Brown**
Vanderbilt University
School of Medicine
Nashville, Tennessee

**Anthony N. Burkitt**
Department of Electrical and Electronic Engineering
The University of Melbourne
Victoria, Australia

**Paul R. Carney**
Departments of Pediatrics, Neurology, and Neuroscience
and
J. Crayton Pruitt Department of Biomedical Engineering
McKnight Brain Institute
University of Florida
Gainesville, Florida

**Daniel Chicharro**
Department of Information and Communication Technology
Universitat Pompeu Fabra
Barcelona, Spain

**Jui-Hong Chien**
Optima Neuroscience, Inc.
Alachua, Florida
and
J. Crayton Pruitt Family Department of Biomedical Engineering
University of Florida
Gainesville, Florida

**R. P. Costa**
Faculty of Sciences and Technology
University of Coimbra
Coimbra, Portugal

**B. Crépon**
Centre de Recherche de l'Institut du Cerveau et de la Moelle épinière
Hôpital de la Pitié-Salpêtrière
and
Epilepsy Unit, Groupe Hospitalier Pitié-Salpêtrière Assistance Publique
Hôpitaux de Paris
Paris, France

**Al W. de Weerd**
Department of Clinical Neurophysiology and Sleep Centre
Dokter Denekampweg
Zwolle, Netherlands

**B. Direito**
Faculty of Sciences and Technology
University of Coimbra
Coimbra, Portugal

**William Ditto**
School of Biological and Health Systems Engineering
Arizona State University
Tempe, Arizona

**A. Dourado**
Faculty of Sciences and Technology
University of Coimbra
Coimbra, Portugal

**Tyler S. Durazzo**
Yale University
New Haven, Connecticut

**Christian E. Elger**
Department of Epileptology
University of Bonn
Bonn, Germany

**Hinnerk Feldwisch-Drentrup**
Bernstein Center for Computational Neuroscience
University of Freiburg
Freiburg, Germany

**Piotr J. Franaszczuk**
Department of Neurology
Johns Hopkins University
School of Medicine
Baltimore, Maryland

**Mark G. Frei**
Flint Hills Scientific, L.L.C.
Lawrence, Kansas

**Dennis Glüsenkamp**
Department of Epileptology
and
Helmholtz Institute for Radiation and Nuclear Physics
University of Bonn
Bonn, Germany

**Jeffrey H. Goodman**
Department of Developmental Neurobiology
New York State Institute for Basic Research
Staten Island, New York
and
Department of Physiology and Pharmacology
State University of New York Downstate Medical Center
Brooklyn, New York

**David B. Grayden**
Department of Electrical and Electronic Engineering
University of Melbourne
Victoria, Australia

**John V. Guttag**
Electrical Engineering and Computer Science Department
Massachusetts Institute of Technology
Cambridge, Massachusetts

**Wytske A. Hofstra**
Department of Clinical Neurophysiology and Sleep Centre
Dokter Denekampweg
Zwolle, Netherlands

**G. Huberfeld**
Centre de Recherche de l'Institut du Cerveau et de la Moelle épinière
Hôpital de la Pitié-Salpêtrière
and
Epilepsy Unit, Groupe Hospitalier Pitié-Salpêtrière Assistance Publique
Hôpitaux de Paris
Paris, France

**Dong-Uk Hwang**
Korea Institute of Oriental Medicine
Daejeon, Republic of Korea

**Leon Iasemidis**
Harrington Department of Bioengineering and Electrical Engineering
Arizona State University
Tempe, Arizona
and
Department of Neurology
Mayo Clinic
Phoenix, Arizona

**Pedro P. Irazoqui**
Weldon School of Biomedical Engineering
Purdue University
West Lafayette, Indiana

**M. Jachan**
Albert-Ludwigs-University
Freiburg, Germany

**John G. R. Jefferys**
Neuronal Networks Group
School of Clinical and Experimental Medicine
University of Birmingham
Birmingham, United Kingdom

**Premysl Jiruska**
Neuronal Networks Group
School of Clinical and Experimental Medicine
University of Birmingham
Birmingham, United Kingdom

**Bharat S. Joshi**
Department of Electrical and Computer Engineering
University of North Carolina
Charlotte, North Carolina

**Karin Jurkat-Rott**
Institute of Applied Physiology
Ulm University
Ulm, Germany

**Stiliyan N. Kalitzin**
Medical Physics Department
Epilepsy Institute of the Netherlands
Heemstede, Netherlands

**Ryan T. Kern**
Optima Neuroscience, Inc.
Alachua, Florida

**Dieter Krug**
Department of Epileptology
and
Helmholtz Institute for Radiation and Nuclear Physics
University of Bonn
Bonn, Germany

**Levin Kuhlmann**
Department of Electrical and Electronic Engineering
University of Melbourne
Victoria, Australia

**Themis R. Kyriakides**
Departments of Pathology and Biomedical Engineering
Yale University
New Haven, Connecticut

**Bruce Lanning**
Thin Film Technologies
ITN Energy Systems
Littleton, Colorado

**M. Le Van Quyen**
Centre de Recherche de l'Institut du Cerveau et de la Moelle épinière
Hôpital de la Pitié-Salpêtrière
Paris, France

**Frank Lehmann-Horn**
Institute of Applied Physiology
Ulm University
Ulm, Germany

**Klaus Lehnertz**
Department of Epileptology
and
Helmholtz Institute for Radiation and Nuclear Physics
and
Interdisciplinary Center for Complex Systems
University of Bonn
Bonn, Germany

**Holger Lerche**
Department of Neurology and Epileptology
Hertie Institute of Clinical Brain Research
University of Tübingen
Tübingen, Germany

**Ronald P. Lesser**
Department of Neurology and Neurosurgery
Johns Hopkins University
School of Medicine
Baltimore, Maryland

**Fernando Lopes da Silva**
Swammerdam Institute of Neuroscience
University of Amsterdam
Amsterdam, Netherlands

**Snezana Maljevic**
Department of Neurology and Epileptology
Hertie Institute of Clinical Brain Research
University of Tübingen
Tübingen, Germany

**Iven M. Y. Mareels**
Department of Electrical and Electronic Engineering
University of Melbourne
Victoria, Australia

**Gregory C. Mathews**
Vanderbilt University
School of Medicine
Nashville, Tennessee

**John G. Milton**
W. M. Keck Science Center
Claremont Colleges
Claremont, California

**Florian Mormann**
Department of Epileptology
University of Bonn
Bonn, Germany

**Gholam K. Motamedi**
Department of Neurology
Georgetown University School of Medicine
Washington, DC

**V. Navarro**
Centre de Recherche de l'Institut du Cerveau et de la Moelle épinière
Hôpital de la Pitié-Salpêtrière
and
Epilepsy Unit, Groupe Hospitalier Pitié-Salpêtrière Assistance Publique
Hôpitaux de Paris
Paris, France

**S. Nikolopoulos**
Centre de Recherche de l'Institut du Cerveau et de la Moelle épinière
Hôpital de la Pitié-Salpêtrière
Paris, France

**Elma O'Sullivan-Greene**
Department of Electrical and Electronic Engineering
University of Melbourne
Victoria, Australia
and
National Information and Communications Technology Australia
Victorian Research Lab
Melbourne, Australia

**Ivan Osorio**
Department of Neurology
University of Kansas Medical Center
Kansas City, Missouri

**Trudy Pang**
Neurology Department
and
Clinical Investigator Training Program
Beth Israel Deaconess Medical Center
and
Harvard/MIT Health Sciences and Technology in collaboration with Pfizer Inc. and Merck and Company
Boston, Massachusetts

**Panos M. Pardalos**
Industrial and Systems Engineering Department
University of Florida
Gainesville, Florida

**Austin R. Quan**
Harvey Mudd College
Claremont, California

**Shriram Raghunathan**
Weldon School of Biomedical Engineering
Purdue University
West Lafayette, Indiana

**Pooja Rajdev**
Weldon School of Biomedical Engineering
Purdue University
West Lafayette, Indiana

**Alexander Rothkegel**
Department of Epileptology
and
Helmholtz Institute for Radiation and Nuclear Physics
and
Interdisciplinary Center for Complex Systems
University of Bonn
Bonn, Germany

**Shivkumar Sabesan**
Department of Neurology Research
Barrow Neurological Institute
St. Joseph's Hospital and Medical Center
Phoenix, Arizona
and
Harrington Department of Bioengineering
Arizona State University
Tempe, Arizona

**J. Chris Sackellares**
Optima Neuroscience, Inc.
Alachua, Florida

**Steven C. Schachter**
Neurology Department
Beth Israel Deaconess Medical Center
Boston, Massachusetts

**Bjoern Schelter**
Center for Data Analysis and Modeling
University of Freiburg
Freiburg, Germany

**Andreas Schulze-Bonhage**
Epilepsy Center
University Hospital
Freiburg, Germany

**Deng-Shan Shiau**
Optima Neuroscience, Inc.
Alachua, Florida

**Ali Shoeb**
Massachusetts General Hospital
Boston, Massachusetts
and
Massachusetts Institute of Technology
Cambridge, Massachusetts

**Joseph Sirven**
Department of Neurology
Mayo Clinic
Phoenix, Arizona

**Didier Sornette**
Swiss Federal Institute of Technology Zurich
and
Swiss Finance Institute
Zurich, Switzerland

**Dennis D. Spencer**
Department of Neurosurgery
Yale University
New Haven, Connecticut

**Matthäus Staniek**
Department of Epileptology
and
Helmholtz Institute for Radiation and Nuclear Physics
University of Bonn
Bonn, Germany

**Matt Stead**
Mayo Systems Electrophysiology Laboratory
Division of Epilepsy and Section of Electroencephalography
and
Department of Neurology
Mayo Clinic
Rochester, Minnesota

**Ortrud K. Steinlein**
Institute of Human Genetics
University Hospital, Ludwig-Maximilians-University
Munich, Germany

**Sridhar Sunderam**
Center for Biomedical Engineering
University of Kentucky
Lexington, Kentucky

**Sachin S. Talathi**
J. Crayton Pruitt Department of Biomedical Engineering
McKnight Brain Institute
University of Florida
Gainesville, Florida

**C. A. Teixeira**
Faculty of Sciences and Technology
University of Coimbra
Coimbra, Portugal

**Jens Timmer**
Freiburg Institute for Advanced Studies
University of Freiburg
Freiburg, Germany

**David M. Treiman**
Department of Neurology
Barrow Neurological Institute
St. Joseph's Hospital and Medical Center
Phoenix, Arizona

**Konstantinos Tsakalis**
Department of Electrical Engineering
Arizona State University
Tempe, Arizona

**M. Valderrama**
Centre de Recherche de l'Institut du Cerveau et de la Moelle épinière
Hôpital de la Pitié-Salpêtrière
Paris, France

**Taufik A. Valiante**
Krembil Neuroscience Center
University Health Network
Toronto Western Hospital
Toronto, Ontario, Canada

**Andrea Varsavsky**
Department of Otolaryngology
The University of Melbourne
Victoria, Australia

**Demetrios N. Velis**
Department of Clinical Neurophysiology
and
Epilepsy Monitoring Unit
Epilepsy Institute of the Netherlands
Heemstede, Netherlands

**Christopher Warren**
Mayo Systems Electrophysiology Laboratory
Division of Epilepsy and Section of Electroencephalography
and
Department of Neurology
Mayo Clinic
Rochester, Minnesota

**Yvonne Weber**
Department of Neurology and Epileptology
Hertie Institute of Clinical Brain Research
University of Tübingen
Tübingen, Germany

**Steven Weinstein**
Pediatric Epilepsy Center
Weill Cornell Medical Center
New York Presbyterian Hospital
New York, New York

**Richard Wennberg**
University of Toronto
Toronto, Ontario, Canada

**Gregory A. Worrell**
Mayo Systems Electrophysiology Laboratory
Division of Epilepsy and Section of
Electroencephalography
and
Department of Neurology
Mayo Clinic
Rochester, Minnesota

**Hitten P. Zaveri**
Department of Neurology
Yale University
New Haven, Connecticut

# Section I

## Foundations of Epilepsy

# 1 Neuroanatomy as Applicable to Epilepsy

## *Gross and Microscopic Anatomy/Histology*

*Taufik A. Valiante*

**CONTENTS**

1.1 Introduction ..... 4
1.2 Gross Anatomy ..... 4
1.3 Cytoarchitecture ..... 6
1.4 Lobes of the Brain ..... 7
1.4.1 Frontal Lobe ..... 7
1.4.1.1 Inferior Frontal Gyrus ..... 8
1.4.1.2 Precentral Gyrus ..... 8
1.4.1.3 Medial Frontal Gyrus: Supplementary Motor Area ..... 10
1.4.1.4 Other Frontal Gyri ..... 10
1.4.1.5 Premotor Area ..... 10
1.4.1.6 Frontal Eye Fields ..... 10
1.4.1.7 Clinical Manifestations ..... 10
1.4.1.8 Prefrontal Area ..... 11
1.4.2 Parietal Lobe ..... 11
1.4.2.1 Primary Sensory Area ..... 11
1.4.3 Occipital Lobe ..... 11
1.4.4 Temporal and Limbic Lobe ..... 12
1.4.4.1 Language and the Temporal Lobe ..... 13
1.4.4.2 Hearing ..... 13
1.4.4.3 Memory ..... 14
1.4.4.4 Amygdala ..... 15
1.4.4.5 Clinical Manifestations of Temporal Lobe Seizures ..... 15
1.4.5 Insula ..... 16
1.5 Thalamus ..... 16
1.6 White Matter ..... 18
1.6.1 Projection Fibers ..... 18
1.6.2 Association Fibers ..... 19
1.6.2.1 Long Association Fibers ..... 19
1.6.2.2 Commissural Fibers ..... 20
1.6.2.3 Short Association Fibers ..... 20
1.6.3 Connectivity ..... 21
References ..... 21

If the brain were simple enough for us to understand it, we would be too simple to understand it.

**—Ken Hill**

## 1.1 INTRODUCTION

This is a brief summary of brain anatomy in the context of epilepsy. It reviews the gross anatomical and some ultrastructural details as a primer for those with little or no clinical orientation. This is by no means exhaustive, and there are ample texts for those wishing more detail (Nieuwenhuys et al. 1988; Carpenter 1991; Sheppard 2004; Andersen et al. 2007; Miller and Cummings 2007). As was so appropriately stated during the Fourth International Workshop on Seizure Prediction (IWSP4) in Kansas City by Walter Freeman, "We don't have a language that describes brain function." We are left then with trying to describe the brain from a structural perspective and implying function from physiological experimentation on animals and humans. It might be equally important to mention that, along with not having a language to describe brain function, we have little way to measure brain function—whatever that might be—if this is in fact what we are doing with various technologies currently at our disposal.

I will describe the various lobes of the brain and what structural and ultrastructural details give rise to these anatomical demarcations. How various regions are wired together will be dealt with through discussion of white matter tracts. Functional subregions relevant to epilepsy and its manifestations will follow from the above lobar demarcations as well as from cellular variability throughout the brain associated with specialized functions of these cellularly distinct regions. There is a more generous discussion of the temporal lobe compared with other lobes, as it is the portion of the brain that has been extensively studied in regard to epilepsy and the region most frequented by neurosurgeons in attempts to ameliorate epilepsy.

## 1.2 GROSS ANATOMY

The human brain weighs, on average, 1350 grams; however, in its native state suspended in nutritious cerebrospinal fluid (CSF), it weighs only 50 grams. It is a highly ordered and exceedingly organized structure with the majority of the brain volume being composed of cells and cellular processes. Hence, the brain is largely composed of the internal components of cells, with only a very narrow space (extracellular space) separating cellular components of the brain. In fact, only about 4% of the human brain volume can be attributed to extracellular space. The remainder of the brain volume can be attributed to neurons and glia, the two primary cellular components of the brain. There are three primary subdivisions of the brain (see Figure 1.1): cerebrum, brain stem, and cerebellum. The last two are not usually implicated in epilepsy and will not be discussed.

The two hemispheres (see Figure 1.2) are separated by the longitudinal or interhemispheric fissure and are covered by a 2- to 5-mm layer of neurons that forms the cortex (like the bark of a tree) or gray matter. Underlying the gray matter is white matter, which represents the cabling of the brain and is composed of axons. Axons convey all or none events to other neurons through the generation of action potentials that are conveyed in a metabolically efficient manner over long distances. The termination of the axon at a synapse generates graded potentials in the postsynaptic cell that will, if large (sufficiently depolarized) enough, cause the postsynaptic neuron to generate an action potential. There are other gray matter components—the largest being the striatum, basal ganglia, and the thalamus—that lie within the core of the brain with interposed white matter. These gray matter structures are not arranged in layers, like the cortex, but form clusters of neurons called ganglia. The two hemispheres are interconnected by a very large white matter bundle called the corpus callosum, which will be discussed in more detail later.

The total surface area of the cortex measures approximately 2500 $cm^2$ ($0.5 \times 0.5$ m), with only one third of it being visible on the exposed surface of the brain (Douglas et al. 2004). The remainder

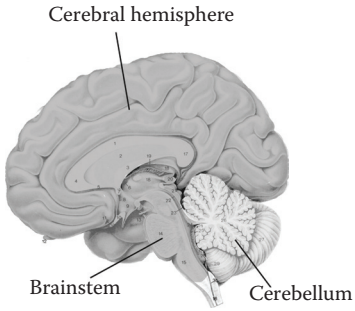


**FIGURE 1.1 (See color insert.)** The human brain. The cerebral hemispheres are paired (not shown), as are the cerebellar hemispheres. The brainstem is not a paired structure and is subdivided into the diencephalon, midbrain, pons, and medulla. Only the cerebral hemispheres and the thalamus are of concern in this chapter, as the other structures of the diencephalon have unclear roles in epilepsy. (Adapted from Nieuwenhuys, R. et al., *The Human Central Nervous System: A Synopsis and Atlas,* Springer-Verlag, New York, 1988. With permission; Carpenter, M. B., *Core Text of Neuroanatomy*, Williams & Wilkins, Baltimore, 1991.)

of the cortex is hidden within sulci (deep clefts) that are lined by cortex (Figure 1.2). The brain matter between these sulci are gyri. Sulci have a somewhat constant pattern between individuals, although this applies mainly to the larger sulci, which are called fissures. The variability of the gyral pattern makes inferences about function from gyral topology inconsistent. Given the laminar profile of the cortex, the electrophysiological manifestations of electrical fields generated at the top (crowns) of the gyri will be different from those generated in the walls of the sulci (Ebersole 2003). The engineering problems that arise from this are left to those more computationally adept than the author. The gyri can, in certain regions of the brain, be lumped together into functionally (and usually histologically) distinct regions called lobes. For example, the frontal lobe is demarcated from the parietal lobe and temporal lobe by the Rolandic fissure posteriorly and the Sylvian fissure

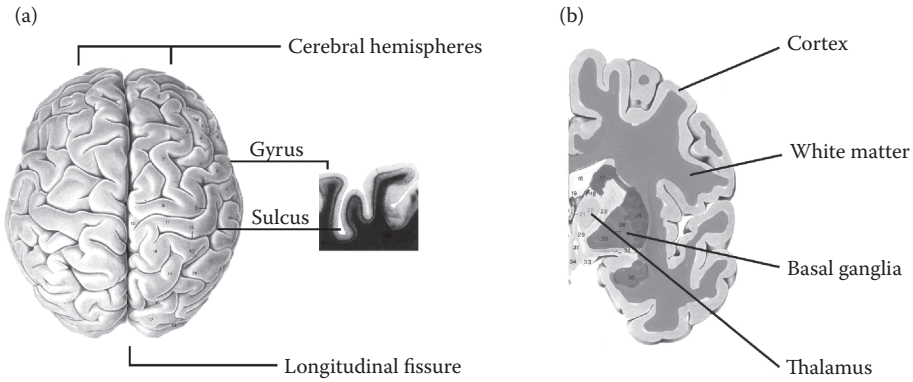


**FIGURE 1.2 (See color insert.)** The hemispheres and general organization. (a) The two hemispheres are separated by the longitudinal fissure. They are connected (although not visible) by the corpus callosum. The inset shows a cross section through the brain and the underlying structure and the relationship of gyri and sulci and how they are manifest on the surface of the brain. This can also be appreciated in (b). (b) Overall organization of the hemisphere. The cortex overlies the white matter that inspisates itself between the deep gray matter structures of the brain—the largest of these deep gray matter structures being the striatum, basal ganglia, and thalamus. (Adapted from Nieuwenhuys, R. et al., *The Human Central Nervous System: A Synopsis and Atlas,* Springer-Verlag, New York, 1988. With permission; Carpenter, M. B., *Core Text of Neuroanatomy,* Williams & Wilkins, Baltimore, 1991. With permission.)

inferiorly, respectively. With these gross demarcations, the frontal lobe can be further partitioned based on the sulcal pattern into various gyri (Figure 1.6).

## 1.3 CYTOARCHITECTURE

In the context of the brain, cytoarchitectonics refers to the study of the laminar organization of the cellular components of the brain. The neocortex has six layers with each $mm^3$ containing approximately 50,000 neurons. It has been suggested that 1 $mm^2$ is the smallest area of cortex that can perform all the functions of a given cortical area (Douglas et al. 2004).

Broadly speaking, neurons can be subgrouped into those that have spines, and those that do not. A spiny neuron, unlike a nonspiny neuron, utilizes the neurotransmitter glutamate (excitatory neurotransmitter), whereas nonspiny neurons utilize gamma amino butyric acid (GABA) (Douglas et al. 2004). Excitation refers to the process of bringing the membrane potential of a given neuron to a more positive potential, and is also referred to as depolarization. Inhibition is the converse of excitation and is also referred to as hyperpolarization. In electrophysiology parlance, and the convention that currents are carried by positive charges, depolarization is a result of an increase in inward current or a decrease in outward current.

As mentioned above, the neocortex has six layers of neurons, and the cellular composition of these layers varies across different brain regions. The various layers and their names are illustrated in Figure 1.3. Broadly speaking, there appear to be three different patterns of cellular constituents, giving rise to cytoarchitecturally distinct types of cortex: (1) koniocortex or granular cortex of sensory areas, which contains many granule and stellate cells; (2) agranular cortex of motor and premotor regions, which is characterized by fewer stellate cells and more pyramidal neurons; and (3) eulaminate or homotypical cortex, which includes much of the association cortices (a cortex that is not primary motor or primary sensory). An example of a cytoarchitecturally distinct region is the primary motor area, also referred to as the motor strip, which is characterized by large pyramidal neurons in layers III and V and almost complete loss of layer 4 (Figure 1.4). In contrast to this primary motor area, the primary visual cortex, which is a primary sensory area, is characterized by a very prominent layer 4

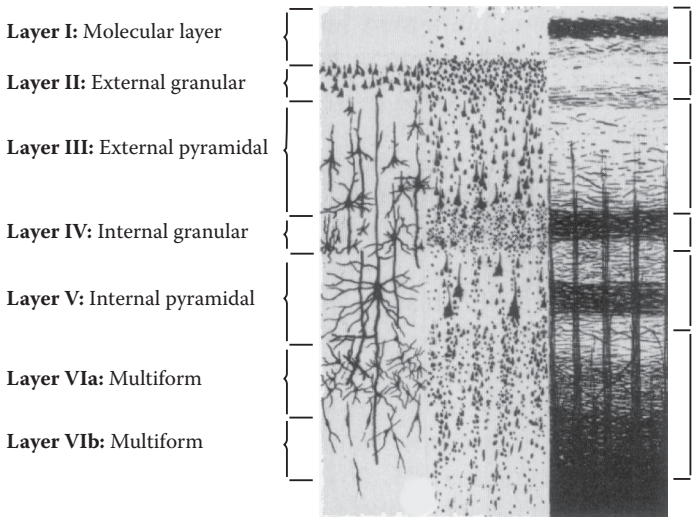


**FIGURE 1.3** Laminar structure of the cortex. A histological section through the human brain displaying the various layers. (From Nieuwenhuys, R. et al., *The Human Central Nervous System: A Synopsis and Atlas,* Springer-Verlag, New York, 1988; Carpenter, M. B., *Core Text of Neuroanatomy*, Williams & Wilkins, Baltimore, 1991. With permission.)

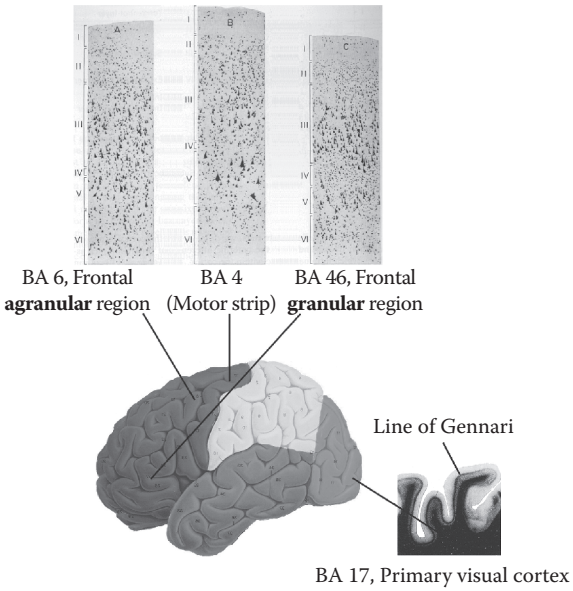


**FIGURE 1.4 (See color insert.)** Regional variability of cortical layering. Three different functional regions are depicted, and their variability in cortical layering. BA 6, or the premotor area, is just one sulcus anterior to the motor strip (primary motor area, BA 6) but lacks the large Betz cells of layer V that are characteristic of the primary motor area. BA 4 has a paucity of inputs from sensory and associational areas and thus has a less conspicuous layer IV, which is more prominent in the BA 46 (dorsolateral prefrontal cortex). In BA 17 (in the occipital lobe), note the very prominent black line (line of Gennari) noted in a gross specimen (not a histological specimen) that is visible without the aid of magnification. This line corresponds to the very prominent layer IV, where the massive thalamic input terminates. The numbers on the hemisphere do not correspond to Brodmann areas. (From Nieuwenhuys, R. et al., *The Human Central Nervous System: A Synopsis and Atlas,* Springer-Verlag, New York, 1988. With permission; Carpenter, M. B., *Core Text of Neuroanatomy*, Williams & Wilkins, Baltimore, 1991. With permission.)

(due to the massive thalamic input from the lateral geniculate nucleus) that is visible with the unaided eye (Figure 1.4). In all areas of the brain, layer IV is where input from the thalamus arrives.

The primary motor and primary visual areas are but two examples of 52 cytoarchitecturally distinct regions of the brain described by Brodmann, a German neurologist (Brodmann 1909). These areas also bear a close relationship to functionally distinct brain regions despite being characterized solely by their cytoarchitectural features. For example, the primary motor area is also known as Brodmann area 4, or BA 4, and the primary visual area is BA 17. This structural regional description will be useful when describing functional specialization within the brain.

## 1.4 LOBES OF THE BRAIN

In this section, I review six lobes of the brain (Figure 1.5), one of which is not truly a lobe, as it is a combination of varied structures and is, thus, a synthetic lobe. Enumerated, these are the frontal, parietal, occipital, temporal, insular, and limbic lobes (synthetic).

### 1.4.1 Frontal Lobe

The frontal lobe is demarcated anatomically from the other frontal lobes by the longitudinal fissure medially and from the parietal lobe posteriorly by the Rolandic fissure. It is the largest of the lobes

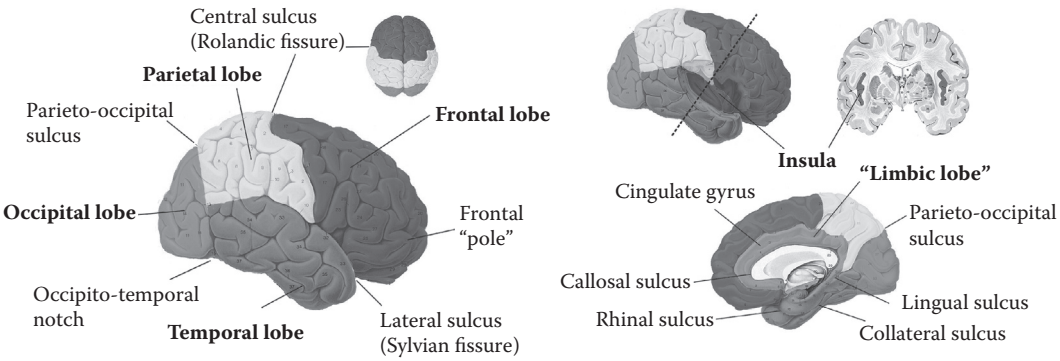


**FIGURE 1.5** **(See color insert.)** Lobes of the brain. Various colors demarcate the different lobes of the brain. Some lobes are demarcated from other lobes by sulci and fissures (deep sulci), whereas others may have rather indistinct margins. The limbic lobe is a conglomerate of a number of disparate, although functionally related, gyri and subcortical structures. It is thus referred to as a synthetic lobe. The insula is shown hidden under the temporal and frontal gyri in a cutaway. The coronal section of the brain is taken along the dotted line. (From Nieuwenhuys, R. et al., *The Human Central Nervous System: A Synopsis and Atlas,* Springer-Verlag, New York, 1988. With permission; Carpenter, M. B., *Core Text of Neuroanatomy*, Williams & Wilkins, Baltimore, 1991. With permission.)

of the brain comprising one third of the hemispheric surface. From an epilepsy surgery perspective, it is the second most common lobe in which epilepsy surgery is performed.

#### 1.4.1.1 Inferior Frontal Gyrus

The three gyri on the lateral surface of the frontal lobe are numbered from 1 to 3 and enumerated as F1, F2, and F3 (the F indicating frontal) (Figure 1.6a and 1.6d). These are also referred to as the superior, middle, and inferior frontal gyri, respectively. The inferior frontal gyrus, or F3, is functionally unique, as it "contains Broca's area," a region within the dominant hemisphere that is important for the production of speech (see Figure 1.10). Hemispheric dominance refers to the hemisphere in which verbal functions reside, including the reception and transmission of language, which is usually on the left side of the brain. Broca's area is comprised of two of the three parts (pars) of the inferior frontal gyrus: the pars triangularis and the pars opercularis (Figure 1.6a). There is a third part of F3 termed the pars orbitalis, which is usually not involved in speech generation. It was by studying the brain of an individual with damage to this area that Broca deduced this region of the brain to be involved in speech production. At the time of this discovery, there was ongoing debate as to whether the bumps on an individual's head could be used to localize brain function, an area of study called phrenology. To this Broca remarked, "I thought that if ever there were a science of phrenology, this was the phrenology of the convolutions, and not the phrenology of bumps" (Broca 1861). The disorder of speech generated by damage to this area is termed a nonfluent aphasia, as the individual's speech generation is impaired.

#### 1.4.1.2 Precentral Gyrus

The precentral gyrus, also known as the motor strip, has already been mentioned. It resides just anterior to the Rolandic fissure (central sulcus), being the most posterior gyrus of the frontal lobe (Figure 1.6b). This is the primary motor area, the major output center to bulbar (brainstem) and spinal motor neurons that are involved in generating voluntary motor activity. The organization of the motor strip is somatotopically organized, which means that neighboring neurons within the motor strip control neighboring body parts and, thus, the physical organization of the motor strip is similar to the physical organization of the human body (Penfield and Rasmussen 1950). This functional specialization of the motor strip is mirrored by its cytoarchitectural organization, being characterized

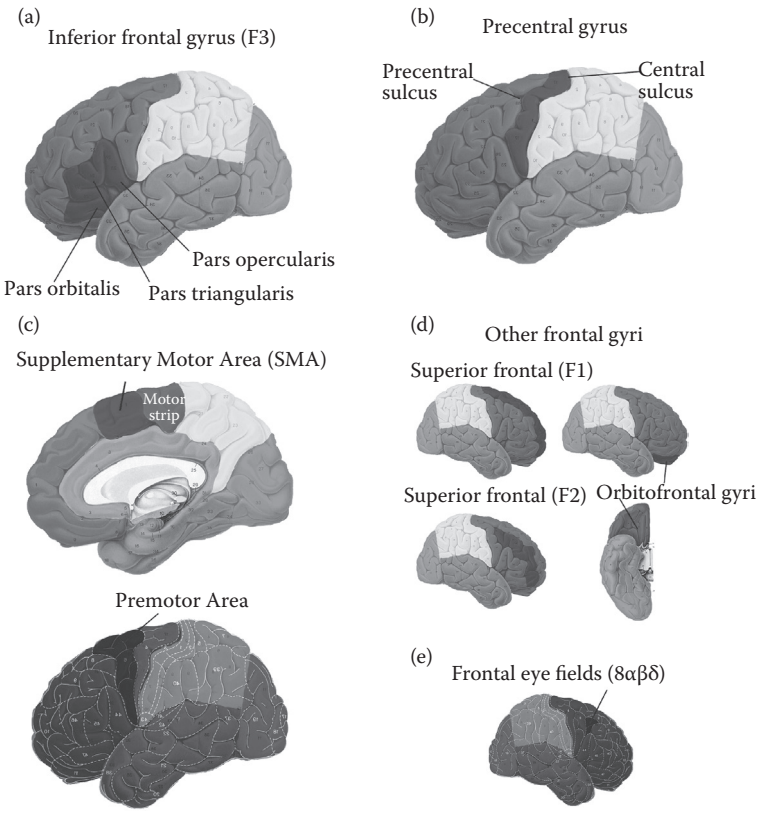


**FIGURE 1.6 (See color insert.)** Various frontal gyri and functional regions within the frontal lobe. (a) The inferior frontal gyrus and its various divisions are shown as a darker blue. Pars orbitalis and pars triangularis comprise Broca's area. (b) Precentral gyrus, also known as the motor strip, is shown in dark blue and is demarcated anteriorly by the precentral sulcus and posteriorly by the central sulcus (also known as the Rolandic fissure). (c) The supplementary motor area (SMA) and its continuation on the lateral surface of the hemisphere as the premotor area. (d) Other frontal gyri, superior (F1), middle (F2), and orbitofrontal. (e) Frontal eye fields, BA 8αβδ, involved in voluntary movements of the eyes. (From Nieuwenhuys, R. et al., *The Human Central Nervous System: A Synopsis and Atlas,* Springer-Verlag, New York, 1988. With permission; Carpenter, M. B., *Core Text of Neuroanatomy*, Williams & Wilkins, Baltimore, 1991.)

by large layer V pyramidal neurons called Betz cells. During surgery, this region can be stimulated with current, giving rise to motor responses that aid in its identification (Penfield and Rasmussen 1950). The movements that result from stimulating this area are usually simple rudimentary movements of the limbs, hands, and face. It has the lowest threshold for generating an electrophysiological response of any other region of the brain. The output of this region is via the corticospinal tract, a white matter projection system that will be described later.

At this point, it is likely obvious to the reader that there are specific areas of the brain that appear to be dedicated to specific functions. This was not always so obvious, and it was the pioneering work of two German physicians, Fritsch and Hitzig, who in 1870 showed not only that, "One part of the convexity of the cerebrum of the dog is motor (this expression is used in the sense of Shiff), another part is not motor," but the brain is also electrically excitable (Fristsch and Hitzig 1870). In their experiments that were carried out in the home of one of the physicians' mothers, the exposed cerebrum of the dog was shown to be excitable by stimulation with electrical current via bipolar electrodes and observation of motor activity in the limbs of the animal. The localization of cerebral function was refined in animals by Ferrier (1876) and then brought into the realm of the human

brain by Wilder Penfield. Penfield was able to map the human brain in conscious patients during surgery for epilepsy by electrically stimulating the brain and having the patient explain their feelings or observing their movements. Through this, he was able to essentially map out important cerebral functions including sensory, motor, speech, vision, hearing, memory, sensory perceptions, and dreams (Penfield and Rasmussen 1950).

#### 1.4.1.3 Medial Frontal Gyrus: Supplementary Motor Area

The supplementary motor area (SMA), which was identified by Penfield, is in the medial aspect of the hemisphere, just anterior to the primary motor area (Figure 1.6c). When stimulated, it produces motor activity different from that obtained from stimulation of the motor strip in that it creates synergistic movements of a large number of muscle groups on the side opposite to the stimulation. This area of the brain is likely involved in the programming of complex motor movements, the initiation of movements, and the coordination of bimanual activity. This region is also somatotopically organized. Removal of this area results in a transient paralysis of the opposite (contralateral) side of the body and, if the dominant SMA is removed, there is transient mutism as well.

#### 1.4.1.4 Other Frontal Gyri

The other frontal gyri, F2, F3, and orbital gyri, do not have somatotopically and uniquely localized functions (Figure 1.6d). What appears to be the case for these gyri is that portions of them combine into functionally and cytoarchitecturally discrete regions and are better demarcated by Brodmann areas than gyral anatomy.

#### 1.4.1.5 Premotor Area

The premotor area is a continuation of the SMA, but on the lateral aspect of the hemisphere (see Figure 1.6c). This region is referred to as BA 6 and lies in the precentral gyrus, spanning a number of the frontal gyri, anterior to the motor strip, which is BA 4. Cytoarchitecturally, it is referred to as agranular cortex, since it lacks layer 4. This region is involved in sensorially guided voluntary movements (Geschwind and Iacoboni 2007). Neurons in this region are also activated by visual, auditory, and somotosensory stimuli. Electrophysiologically, this region has a higher threshold than the motor strip, and cytoarchitecturally it resembles the primary motor area, except that it does not contain Betz cells.

#### 1.4.1.6 Frontal Eye Fields

This small region of the frontal lobe in BA 8αβδ is thought to be involved in voluntary eye movements in the absence of visual stimuli; for example, the initiation of purposeful rapid eye movements toward a target in the visual field—also known as saccades (Figure 1.6e) (Boxer 2007). Stimulation of this area causes deviation of the eyes away from the side of stimulation. It is thus thought that this region generates the "versive" or eye movements away from the side where a seizure is occurring.

#### 1.4.1.7 Clinical Manifestations

The clinical manifestations of seizures arising from the various frontal regions relate to either an excessive activation of this region during the seizure or underactivity during periods between seizures (interictal periods). For example, a seizure that begins in the motor strip will be accompanied by repetitive movement of the part of the body in which the excessive synchronous activity is occurring. Likewise, a seizure focus within the frontal lobe may manifest in the interictal period as changes in frontal lobe function related to the planning or sequencing of daily events—a cognitive process that falls under the rubric of executive function. Another example would be a seizure within the frontal lobe involving the frontal eye fields, which would cause the eyes to deviate to the side opposite to where the seizure is occurring—so-called versive movement of the eyes. Conversely, during the interictal period, one might observe saccadic smooth pursuit, where the eyes make small jumps as one tracks a moving object rather than smoothly following the tracked object.

#### 1.4.1.8 Prefrontal Area

This is an exceedingly expansive region that is thought to involve such diverse functions as attention, awareness, personality, emotion, sensory perception, speech and language, memory, and executive function.

### 1.4.2 Parietal Lobe

#### 1.4.2.1 Primary Sensory Area

Juxtaposed to the primary motor area in the frontal lobe, and just behind the Rolandic fissure, is the primary sensory area (Figure 1.7). Like the primary motor area, it is somatotopically organized and is involved in discriminative touch sensation. It is composed of three Brodmann areas: BA 3, 1, 2. Area 3a receives information from area 1a muscle afferents and BA 3b from cutaneous stimuli. Area 1a receives a combination of cutaneous and deep receptor input and area 2 receives information from stretch receptors (Carpenter 1991). It is beyond the scope of this chapter to detail the sensory system; however, this region is the termination of thalamic efferents (thalamic outputs) that send sensory stimuli to the brain. Information that arrives here includes fine touch and vibration sensation, and the position sense of the joints that is required for accurate guidance of limb movement. Some pain information arrives here, albeit pain sensation is primarily processed in other parts of the brain.

When this area of the brain is stimulated, for example, while surgery is being performed in and around this region, the individual will describe a sensation of tingling, numbness, or electricity. Pain is never experienced here during electrical stimulation of this area of the brain. Removal of this area can be functionally devastating for the individual. Although motor strength is preserved, the limb is extremely hard to control as feedback during voluntary activity is lost, and the limb will often flail about violently.

### 1.4.3 Occipital Lobe

The occipital lobe is the lobe of the brain that is primarily involved in visual perception (Figure 1.8). On the lateral surface of the brain, its demarcations from the temporal lobe are not distinct (Figure 1.5) as there is no sulcal boundary between these two lobes. Medially, however, it is clearly demarcated from the parietal lobe by the parieto-occipital sulcus.

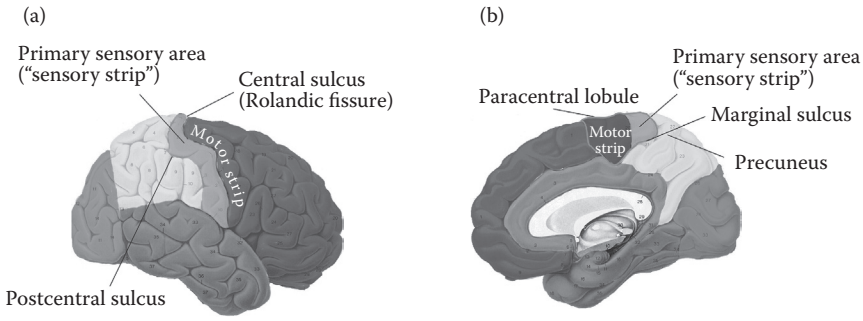


**FIGURE 1.7 (See color insert.)** Primary sensory area. (a) Lateral view of the primary sensory area in dark yellow, separated from the motor strip by the central sulcus. (b) It continues, as does the primary motor area on the medial aspect of the hemisphere. The motor strip plus the sensory area are together referred to as the paracentral lobule (outlined in orange). (From Nieuwenhuys, R. et al., *The Human Central Nervous System: A Synopsis and Atlas,* Springer-Verlag, New York, 1988. With permission; Carpenter, M. B., *Core Text of Neuroanatomy*, Williams & Wilkins, Baltimore, 1991.)

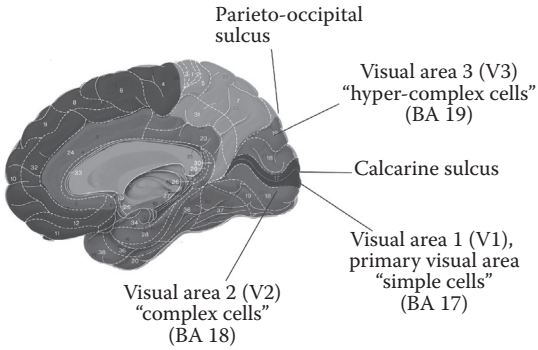


**FIGURE 1.8 (See color insert.)** Occipital lobe and vision. A medial view of the cerebral hemisphere with a superimposed map of Brodmann areas. The occipital lobe is demarcated from the parietal by the parieto-occipital sulcus. Concentrically arranged around the calcarine sulcus are visual areas of increasing functional complexity. These functionally distinct regions correspond to cytoarchitecturally distinct Brodmann areas. Information "radiates" out from the BA 17 to be processed further. This information is then sent forward (not shown) in two visual streams: the dorsal and ventral streams that subserve different aspects of visual perception. (From Nieuwenhuys, R. et al., *The Human Central Nervous System: A Synopsis and Atlas,* Springer-Verlag, New York, 1988. With permission; Carpenter, M. B., *Core Text of Neuroanatomy*, Williams & Wilkins, Baltimore, 1991. With permission.)

The occipital lobe is the first step in a complex circuit and represents the region to which the thalamus, specifically the lateral geniculate nucleus (LGN), projects. It is rather interesting that, in this area unlike in other areas of the brain, one begins to appreciate how complex representations are built of simpler representations (Kuffler et al. 1984). Simple cells in the primary visual area (BA 17) respond to oriented bars of light and will only respond to bars of light that are oriented at a specific angle on the retina. Visual area II, or the secondary visual area, is composed of complex cells that respond to a specifically oriented bar of light moving across the visual field. Even further refinements to detection are made in BA 18, where hypercomplex cells respond only to lines of a certain length that have a specific angle and a specific ratio of light-to-dark contrast.

The organization of the input in the primary visual cortex is retinotopic, which means that a specific region of the retina of the eye projects to a specific region of the brain and the physical relationships between different regions of the retina are maintained in the brain. It is important to note that each occipital lobe receives input from the contralateral visual field of each eye. Thus, the right hemifield (the visual field is split vertically) of each eye is transmitted to the left occipital lobe. Interestingly, the input from each eye remains segregated, resulting in the majority of the neurons in BA 17 being influenced independently by each eye. Thus, input from the two eyes remains segregated yet adjacent to each other, forming what are termed ocular dominance columns. Furthermore, neural assemblies that respond to a given orientation of a bar of light are organized adjacent to each other.

Damage to this region of the brain causes a homonymous hemianopsia, which is bilateral loss of vision on the side opposite the lesion in a vertical plane. Excessive activity in this region of the brain, either during a seizure or a migrainous attack, can result in both positive phenomena like flashing lights (scintillations), or negative phenomena like black spots (scotomata). The scotomata are thought to arise from regions of the brain that are undergoing a depolarizing blockage, whereas the scintillations arise from hypersynchronous activity within neuronal populations.

### 1.4.4 Temporal and Limbic Lobe

The temporal lobe is the most heterogeneous of the lobes with an isocortical (cortex containing six layers) mantle that hides both mesocortical (a less than six-layered cortex) and allocortical (a three-

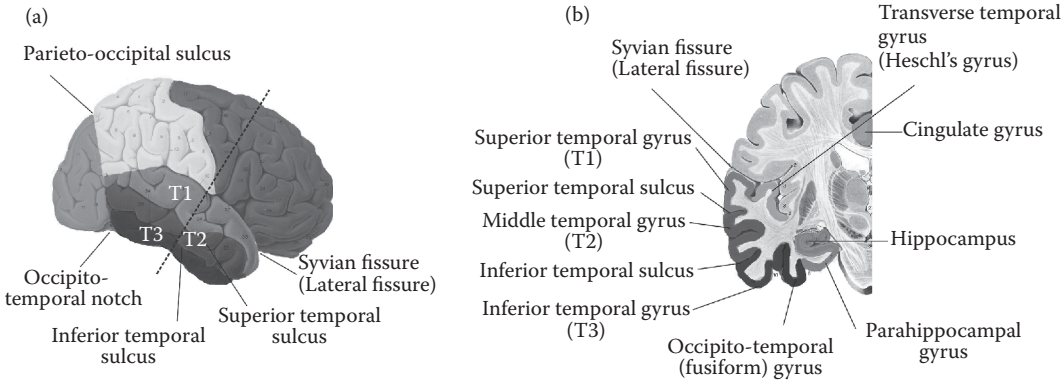


**FIGURE 1.9 (See color insert.)** The temporal lobe: (a) Superior (T1), middle (T2), and inferior (T3) temporal gyri are shown in varying shades of green. The posterior demarcation of the temporal lobe is indistinct from the parietal and occipital lobes. (b) A cross-section at the level shown by the dotted line in (a). The transverse temporal gyrus (Heschl's gyrus) and the basal temporal gyri (occipitotemporal and parahippocampal) now become visible, as well as the hippocampus. The hippocampus and the parahippocampal gyrus compose part of the limbic lobe, as well as the cingulate gyrus. (From Nieuwenhuys, R. et al., *The Human Central Nervous System: A Synopsis and Atlas,* Springer-Verlag, New York, 1988. With permission; Carpenter, M. B., *Core Text of Neuroanatomy*, Williams & Wilkins, Baltimore, 1991.)

layered cortex) regions of the temporal lobe. Both functionally and from an epilepsy perspective, the temporal neocortex is distinguished from the mesial (deep) temporal lobe structures that compose the "limbic lobe" (Figure 1.5). The temporal lobe is clearly demarcated from the frontal lobe by the Sylvian fissure, but posteriorly, its demarcation from the parietal and occipital lobe is somewhat arbitrary (see Figure 1.9).

The temporal neocortex exists both on the lateral aspect and base of the temporal lobe on the floor of the middle cranial fossa. Laterally, the exposed temporal neocortex consists of the superior, middle, and inferior temporal gyri: T1, T2, and T3, respectively. At the base of the temporal lobe is the occipital temporal gyrus—which is the last of the neocortical gyri—that is then followed more medially (toward the center of the head) by the parahippocampal gyrus, which is part of the limbic lobe (Figure 1.9).

#### 1.4.4.1 Language and the Temporal Lobe

Language is, in part, a function that is localized to the neocortex of the dominant hemisphere, which is usually the left hemisphere. Stimulation of the Broca's area (Figure 1.10) results in speech arrest, whereas stimulation within the temporal lobe and within the appropriate location—which varies from person to person (Ojemann et al. 1989)—results in an anomia, which is the inability to name things. Regions within the brain that are involved in naming appear to be close (in physical distance) to Wernicke's area (Figure 1.10). Damage to Wernicke's area results in what is called a receptive aphasia, where the individual is unable to understand what is being said to them. Thus, they would be unable to understand even simple verbal commands.

#### 1.4.4.2 Hearing

The temporal lobe is also involved in hearing, a function closely allied to speech. The primary auditory area consists of areas 41, and 42 of Brodmann, which are contained within the transverse temporal gyri—also known as Heschl's gyrus (Figures 1.9 and 1.10). This region of the temporal lobe receives fibers from the medical geniculate nucleus (lateral geniculate is for vision), a portion of the thalamus. This region of the brain is tonotopically organized, meaning that different frequencies are represented in different regions of the temporal lobe. Information is then transferred via short

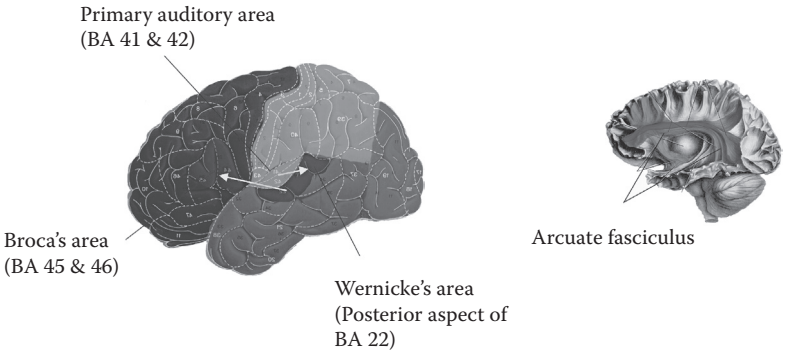


**FIGURE 1.10** **(See color insert.)** Speech and audition. The primary auditory area (BA 41 and BA 42) shown in orange. Through short association fibers (subcortical u-fibers) information is transferred from the primary auditory area to BA 22, which is the posterior aspect of the superior temporal gyrus (which includes Wernicke area), to Broca's area (BA 45 and BA 46) via the arcuate fasciculus (as shown). (From Nieuwenhuys, R. et al., *The Human Central Nervous System: A Synopsis and Atlas,* Springer-Verlag, New York, 1988. With permission; Carpenter, M. B., *Core Text of Neuroanatomy*, Williams & Wilkins, Baltimore, 1991. With permission.)

association fibers (described later) to Wernicke's area, which surrounds this region. Wernicke's area communicates with Broca's area in the generation of speech (Figure 1.10) via the arcuate fasciculus.

#### 1.4.4.3 Memory

In the context of epilepsy and surgery for epilepsy, memory is an important aspect of temporal lobe function. Memory can be categorized into various types, with the mesial (or deep part of the temporal lobe) being involved in episodic and associational memory. We are all familiar with this type of memory, as memory for autobiographical events is one type of episodic memory. The two structures within the temporal lobe that are thought to be intimately involved in memory are the hippocampus and the parahippocampal gyrus and are the most common sites from where seizures are generated (Valiante 2009). These structures appear to be involved not only in storing memory (encoding) but also in recollection of memories (Moscovitch et al. 2005).

The medial temporal lobe containing the hippocampus and parahippocampal gyrus are the most common structures removed during temporal lobe surgery. Removal of these regions in the appropriately selected patient can result in an approximately 80% chance of seizure-freedom (McIntosh et al. 2001).

The hippocampus is well visualized on MRI (Figure 1.11), and with newer and more powerful magnets, more details are being described that help identify pathological changes within this structure (Howe et al.). The hippocampus can be divided into postcommissural (this is the portion within the ventricle—fluid filled space of the brain), supracommissural, and the precommissural hippocampus. The reference to "commissural" describes the anatomical relationship of the hippocampus to the corpus callosum, which will be described later. Only the postcommissural hippocampus (green part) can be removed (Figure 1.11). The hippocampus is a unique structure consisting of the paleocortex (the old cortex that has only three layers) with two interlocking c-shaped neuronal sheets, organized in three dimensions. The two sheets form the cornu ammonis (CA), which creates the various CA regions such as the CA1 region, and the dentate gyrus (Duvernoy 2005).

The hippocampus receives afferents from diverse regions of the brain, including all sensory regions, associational regions (regions which are not primarily motor or sensory), the other hippocampus, the hypothalamus (involved in homeostatic and autonomic functions), and fibers from the brainstem. Thus, the hippocampus is a surveillance system for all conscious and autonomic activities that sends projections back to the regions that project to it. An important output system of

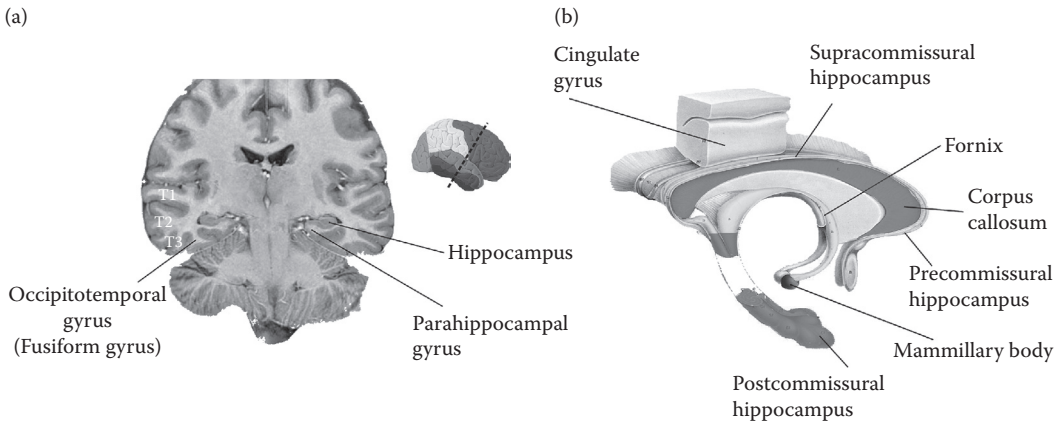


**FIGURE 1.11** **(See color insert.)** The hippocampus. (a) Three Tesla magnetic resonance imagings (MRI) of the human brain shown with the hippocampus (shaded green), and temporal neocortical gyri labeled in white. The MRI section through the brain is taken along the dotted line in the inset. (b) The entire hippocampus, displaying is various components. The mammillary bodies receive output from the hippocampus via the fornix and then project to the anterior nucleus of the thalamus. The cingulate gyrus, shown above the supracommissural hippocampus is part of the limbic lobe. Only that portion of the hippocampus shaded in green can be removed during surgery. (From Nieuwenhuys, R. et al., *The Human Central Nervous System: A Synopsis and Atlas,* Springer-Verlag, New York, 1988. With permission; Carpenter, M. B., *Core Text of Neuroanatomy*, Williams & Wilkins, Baltimore, 1991.)

the hippocampus is the fornix, which consists of about 1 million axons that ultimately project to the anterior nucleus of the thalamus (via the mamillary bodies). Projections to the septal area then relay information back to hypothalamic and brainstem regions.

The circuitry of the hippocampus is among the most well studied of the brain, as it is intimately involved in seizure generation (Andersen et al. 2007). It is a convenient anatomical structure to study, as slices of this structure can generate spontaneous sustained activity. Furthermore, the typical preparation—the transverse hippocampal slice—preserves the majority of the functional connections, including important input circuits.

#### 1.4.4.4 Amygdala

The amygdala is another structure that is removed during surgery for mesial temporal lobe epilepsy. It has been shown to have among the lowest seizure thresholds in the brain (Goddard et al. 1969). This means that the currents required to generate seizure-like activity following repetitive stimulation are lower in the amygdala than other brain regions, including the hippocampus and the parahippocampal gyrus. This region receives input from the olfactory tract (conveys smell information) and the hypothalamus. In its connection to the hippocampus, the amygdala's output is via the stria terminalis to the dorsal nucleus of the vagus and solitary nucleus, both of which are brainstem nuclei. The relevance of these connections becomes apparent when we consider the clinical manifestations of temporal lobe seizures.

#### 1.4.4.5 Clinical Manifestations of Temporal Lobe Seizures

Temporal lobe seizures are often but not always heralded by an aura, a sensory or psychological experience that the individuals remember and that is usually followed by a loss of awareness. The aura is recalled since the patient still has the ability to encode it, whereas encoding does not occur during disturbances of consciousness and the individual remains amnestic (unable to remember) for the event. The aura is considered to be a seizure occurring in a focal area of the brain that is not so widespread as to impair consciousness. For example, although it is generally thought that a déjà vu

experience is a glitch in the "matrix," given the involvement of the hippocampus in memory processes, it is not a stretch to consider a déjà vu experience as a result of aberrant activity within this structure. Likewise the association of smells with temporal seizures likely relates to activity within the corticomedial nuclei of the amygdala and the uncus. We Canadians have television commercials that commemorate events in Canadian history and among them is Wilder Penfield's mapping of the human brain that results in the patient re-experiencing the smell of "burnt toast" that is part of the patient's aura. However, the smells associated with auras of temporal lobe origin tend usually to be pungent, unidentifiable smells. Auras can consist of fear and anxiety, which suggest involvement of the central and basolateral nuclei of the amygdala. There can also be autonomic manifestations that relate to the output of the medial temporal lobe to the various brainstem nuclei, in particular the dorsal nucleus of the vagus. The vagus nerve innervates the heart and various abdominal organs. Individuals often describe a rising feeling in their stomach or a lump in their throat, which may be related to abnormal activity within the vagal nuclei.

Once the seizure activity spreads to involve areas of the brain that alter consciousness, the patient becomes unaware of their behaviors and does not encode the activity they are involved in. They are thus amnestic for this period, unable to recall what happened to them. This alteration of consciousness, usually termed loss of awareness or a dysconscious state, is different from unconsciousness. The individual with a loss of awareness is awake, and interacting with their environment, albeit in a most rudimentary way. This type of seizure is termed a complex partial seizure, with the term complex referring to the loss of awareness. An aura then is considered to be a simple partial seizure. The word partial in these terms refers to the fact that it is thought that the seizure is arising from a confined area of the brain, as opposed to a generalized seizure that is thought to involve both hemispheres of the brain simultaneously, usually from the onset of the seizure. During a complex partial seizure, the individual may be involved in automatic behavior like picking and fumbling with their clothes, orofacial automatisms (chewing movements of the mouth), and wandering (Tai et al. 2010). Following a seizure, the individual may be disoriented, feel extremely tired, have a headache, and may have symptoms of psychosis (paranoia, hallucinations, or delusions).

Involvement of neocortical structures can cause negative (loss of function) or positive (de novo sensory or perceptual experiences) manifestations, just as in the mesial temporal lobe. Thus, involvement of the neocortex can result in speech difficulties, auras that consist of hearing music or voices, and word finding problems.

### 1.4.5 Insula

The insula has been considered part of the "limbic" lobe, but this assignment is certainly not consistent. It is hidden by the frontal and temporal lobes and sits deep to both these lobes. Visualization during surgery is made possible by dissecting the sylvian fissure. The insula receives sensory input from the thalamus and the amygdala. It contains the primary areas for taste, and in the dominant hemisphere has been shown to be critically involved in speech production (Dronkers 1996). It appears to be involved in the emotional experience of olfaction (smell), taste, visceral sensations, and autonomic inputs (Carpenter 1991). For example, it is thought that the insula is, along with the primary somatosensory area, partly responsible for the conscious perception of one's heart beat (Craig 2009).

Seizures that arise from the insula may appear to be, for all intent and purpose, both clinically and electrophysiologically like temporal lobe seizures. A unique aspect of seizures that arise from the insula is that they may be associated with hypersalivation, reflecting its connection to autonomic structures.

## 1.5 THALAMUS

The thalamus is a paired gray matter structure that sits at the top of the brainstem, deep to the cerebral cortex. It is situated on either side of the third ventricle. The ventricles are structures that

produce and contain CSF. The thalamus sits in close proximity to the hypothalamus and is composed of a large number of nuclear groups, arranged in a complex three-dimensional structure.

This structure is part of the diencephalon, along with the epithalamus, hypothalamus, and subthalamus. The thalamus has reciprocal connection to the cortex. Projections to and from the cortex that initially go through the striatum form a number of distinct cortical–subcortical circuits that are thought to be involved in a spectrum of activities from releasing motor programs to conscious awareness. All sensory information except for olfactory information is relayed through the thalamus, ultimately to converge on their respective sensory areas. The idea of a "relay" is a rather simplistic mechanistic appellation and the thalamus would be more appropriately described as an integrator of widely disparate information destined for the cerebral cortex and coming from the cerebral cortex. Its rather extensive input–output relationship becomes apparent in Figure 1.12.

From a seizure perspective, the thalamocortical circuitry has been extensively studied (Steriade and Deschenes 1984). Unlike the focal epilepsies (as described elsewhere in this work), the thalamus has been implicated in the generation and propagation of generalized seizures. Generalized seizures have the electrophysiological hallmark of bilateral synchronous activity across the two hemispheres. Examples of this type of epilepsy are "absence" seizures, which are characterized by bilaterally synchronous activity at 3 Hz in both hemispheres. The thalamocortical circuitry, or cortical–subcortical circuits, that have been implicated in the generation of these types of seizures posited a novel mechanism that is largely dependent on inhibitory circuits (Kim et al. 1997).

The functional implications of seizures or damage to the thalamus are multiple. The thalamus is important in two aspects of consciousness: arousal and content. Arousal is the state of being awake, the intuitive understanding of having ones eyes open spontaneously. The aroused brain, however, has a specific electrophysiological signature characterized by an abundance of high-frequency activity, which appears on visual inspection (in general) to be aperiodic in nature (Ebersole and Pedley 2003). The unaroused (sleep or anesthesia to some extent) brain is usually characterized by an abundance of high-amplitude, low-frequency activity, decreased high-frequency activity, and certain stereotypical electrophysiological signatures that appear to occur in a seemingly periodic pattern (Ebersole and Pedley 2003). The transition from aroused to unaroused, for example, from wakefulness to sleep, is thought to fundamentally involve the thalamus and to be mediated by its specific connections to the ascending reticular activating system (ARAS). The ARAS is one of two

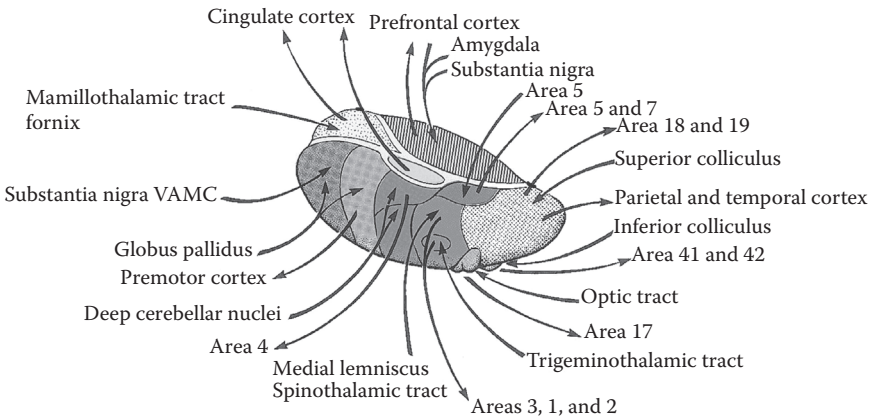


**FIGURE 1.12 (See color insert.)** Input-output of the thalamus. Arrows projecting toward the thalamus represent afferent (incoming) information flow, whereas arrows projecting away from the thalamus represent efferent (outgoing) information. The listed structures are either recipients or originators of thalamic informational flow. (From Nieuwenhuys, R. et al., *The Human Central Nervous System: A Synopsis and Atlas,* Springer-Verlag, New York, 1988; Carpenter, M. B., *Core Text of Neuroanatomy*, Williams & Wilkins, Baltimore, 1991. With permission.)

ascending systems encompassing an anatomically diffuse conglomeration of brainstem nuclei that sends projections to the rostral intralaminar nuclei of the thalamus. From here, one can envisage a sprinkler-type arrangement, with the intralaminar nuclei essentially "showering" the entire cerebral cortex with neurotransmitters that increase cortical excitability.

The "content" aspect of consciousness that is associated with our aroused state and sleep states as well—particularly rapid eye movement (REM) sleep—is functionally a result of the extensive cortical–subcortical circuitry, as mentioned above (Chow and Cummings 2007). It is this circuitry that has been implicated in the generation of widespread synchronization and desynchronization during physiological and pathological states (Llinas et al. 1998).

## 1.6 WHITE MATTER

The cerebral localization of function necessitates that functionally specialized regions of the brain be connected to each other so that information from disparate regions of the brain can be integrated. The term integration has been used before, and I will leave it to the reader's gestalt as to what is meant by this rather nebulous term. As mentioned above, we scarcely have the language or tools to describe what the brain does, but we know that it does something to make us aware of ourselves and our environment. Integration occurs through connectedness, and this connectedness can occur on different physical scales—short, medium, and long range—and is accomplished by white matter structures within the brain.

White matter, so described because it looks white in the real brain, lies below the neocortex and forms another "core" of the cerebral hemisphere (Figure 1.2b). It is interposed within each hemisphere between the cortex and the subcortical gray matter structures, as well between the subcortical structures and between the two hemispheres. It is composed of axons, the equivalent of electrical cables, of varying diameter and insulation thickness. Larger, more heavily insulated axons conduct faster and use less energy that smaller uninsulated fibers, since conduction along these larger axons is saltatory. These larger axons thus tend to be more efficient and, hence, compose the white matter core of the brain.

Wiring the brain comes at a price, both metabolically and space-wise. However, counter intuitively, each $mm^3$ of white matter contains 9 m of axons, whereas each cubic millimeter of gray matter contains 3 km of axons (Douglas et al. 2004). Thus, if one were to try to fuse 100 cortical areas together to avoid using white matter, the cortical volume would increase by 10-fold. Eliminating white matter would result in an increase in intra-areal volume that would far exceed the reduction in interareal axon volume, whereas connecting everything via white matter tracts would be metabolically exorbitant. Somewhere in between is a balance of these two types of architecture, and the brain seems to balance the two rather well.

White matter comes in three "flavors": projection fibers, association fibers, and commissural fibers. Projection fibers convey impulses to and from the cortex, association fibers convey impulses between cortical regions of the same hemisphere, and commissural fibers convey impulses between the two hemispheres.

### 1.6.1 Projection Fibers

Projection fibers are the "long-range" fibers within the brain that convey information either away from the cortex or toward it and do not terminate within another cortical area or arise from another cortical area. For example, fibers destined to move one's finger arise in BA 4, the motor strip, and terminate in the spinal cord, about 1 m away. The fibers that send information from the cortex (efferent fibers) arise in the deep layers of the cerebral cortex, and fibers going toward the cortex (afferent fibers) that terminate in more superficial layers of the cortex form a broad sheet of white matter called the corona radiata (Figure 1.13).

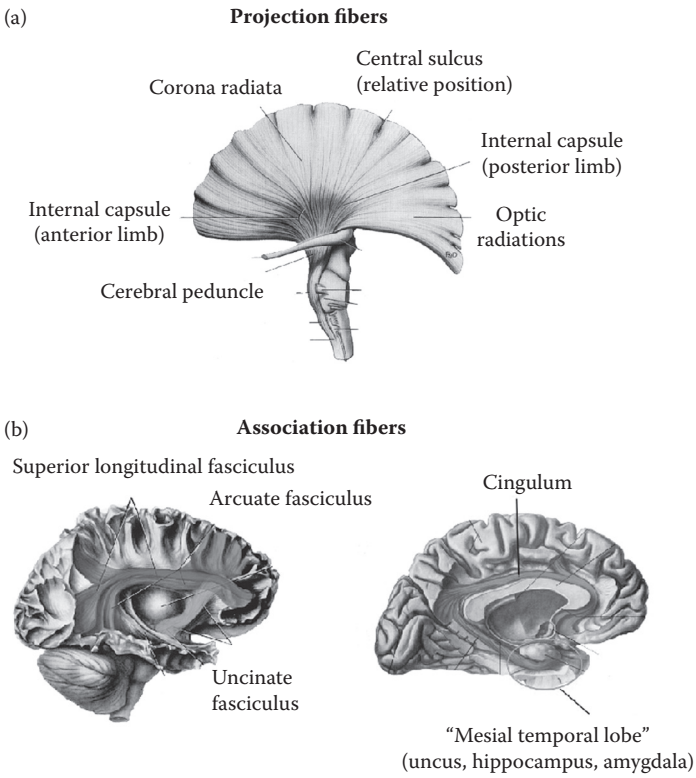


**FIGURE 1.13 (See color insert.)** White matter—projection and association fibers. (a) The projection fibers going to and away from the cortex form a large fan-like structure termed the corona radiata. Shown are fibers projecting away from the cortex (internal capsule) and others projecting toward the cortex like the optic radiations that are transmitting visual information to the occipital lobe (BA 17, see Figure 1.12). (b) Association fiber tracts, also known as fascicles, connect different cortical regions to one another (see text for details). (From Nieuwenhuys, R. et al., *The Human Central Nervous System: A Synopsis and Atlas,* Springer-Verlag, New York, 1988. With permission; Carpenter, M. B., *Core Text of Neuroanatomy*, Williams & Wilkins, Baltimore, 1991. With permission.)

### 1.6.2 Association Fibers

These types of fibers interconnect cortical areas within the same hemisphere and are of two types: short and long. Short association fibers interconnect adjacent gyri, whereas long association fibers interconnect regions of the cortex within different lobes.

#### 1.6.2.1 Long Association Fibers

There are four primary long association fiber systems termed "fascicles," which is another term for a bundle. Thus, a fascicle is composed of a large number of individual axons. The uncinate fasciculus interconnects the orbitofrontal gyri, which are those gyri that sit at the base of the frontal lobe (Figure 1.6d) with parts of the temporal lobe. Another frontal–temporal fascicle is the arcuate fasciculus that interconnects the frontal lobes to the more posterior portions of the temporal lobe. This fasciculus, among other functions, is thought to transmit information from Wernicke's area to Broca's area, two areas that are important in language. Damage to this fasciculus results in what has been termed "conduction aphasia"—referring to the conduction of information from Wernicke's area to Broca's area. The superior longitudinal fasciculus interconnects the frontal lobes to the

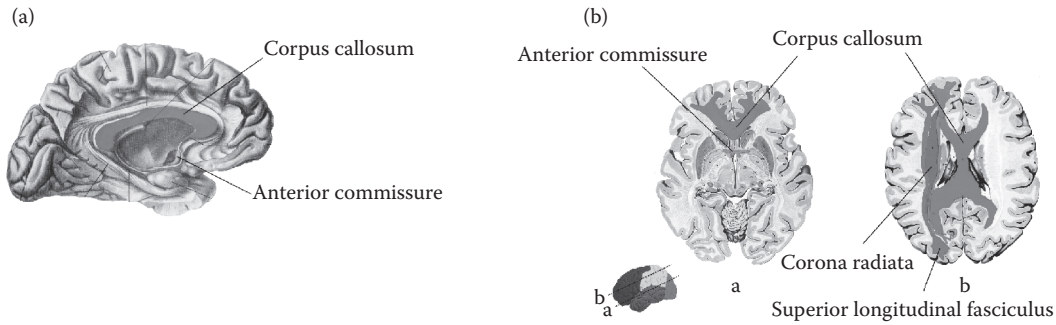


**FIGURE 1.14 (See color insert.)** White matter—commissural fibers. (a) A medial view of the hemisphere showing the massive corpus callosum in dark green, and the smaller anterior commissure in lighter green. (b) Two cross-sections of the brain at different levels. Note the layering of the various types of white matter tracts. (From Nieuwenhuys, R. et al., *The Human Central Nervous System: A Synopsis and Atlas,* Springer-Verlag, New York, 1988. With permission; Carpenter, M. B., *Core Text of Neuroanatomy*, Williams & Wilkins, Baltimore, 1991. With permission.)

occipital and parietal lobes. These different fascicles are depicted in Figure 1.13b. The cingulum is the principal association fiber pathway on the medial aspect of the hemisphere contained within the cingulate gyrus (Figure 1.5). This fasciculus connects the medial frontal and parietal lobes with the parahippocampal gyrus and other mesial temporal lobe structures.

#### 1.6.2.2 Commissural Fibers

Commissural fibers convey information between the two hemispheres. The corpus callosum is the largest of the "commissures," interconnecting vast areas of the two cerebral hemispheres, whereas the anterior commissure is much smaller and interconnects the middle and inferior temporal gyri of the two hemispheres and a small portion of the olfactory bulbs (Figure 1.14).

The corpus callosum reciprocally interconnects all of the lobes of the brain with their corresponding (homologous) lobe on the other side of the brain. It contains 300 million axons, which pales in comparison to the 10 billion neurons and 200 trillion synaptic connections within the cerebral hemispheres. It has been estimated that about 2%–3% of all the cortical neurons in the frontal lobe send projections to the contralateral hemisphere (Lamantia and Rakic 1990). Higher order associational areas (those areas most removed, from a functional perspective, from primary sensory areas) have the greatest density of connections, whereas primary sensory and motor areas have the least. The corpus callosum carries both excitatory and inhibitory connections and is thought to be involved in the integration and transmission of information between the two hemispheres. Thus, it has been postulated that seizure activity can, via the corpus callosum, be transmitted from one hemisphere to another. Based upon this assumption, sectioning of the corpus callosum is done in an effort to palliate individuals with a specific type of seizure, called atonic seizures. Sectioning of the corpus callosum, or a "corpus callosotomy," which means making a hole in the corpus callosum, is rarely curative (Engel 1993).

This homologous connectivity has been beautifully demonstrated in chronic models of epilepsy. In fact, the first chronic model of epilepsy involved placing alumina cream on one motor cortex of nonhuman primates and recording seizure-like activity from the other (contralateral or on the other side) motor cortex—a so-called mirror focus (Harris and Lockard 1981).

#### 1.6.2.3 Short Association Fibers

Short association fibers interconnect adjacent gyri and are often referred to as subcortical U-fibers. These fibers form a "U" in the sense that they travel from one crown of a gyrus through the base of the sulcus and then back up to the crown of the adjacent gyrus (Figure 1.2).

### 1.6.3 Connectivity

It is thought that short-range fibers increase local computational ability, whereas long-range connections are required to bring distant regions together functionally. The balance achieved within the brain between these two types of connectedness has been described as having small-world network characteristics (Buzáski 2006). Small-world networks remain clustered through local connections but have devised a simple strategy to bring these clusters closer together through the reduction of path length. From seminal work on graph theory, it has been shown that by replacing 2% of the short-range connections with long-range connections, local architecture is robustly preserved, while the distance between any two clusters (for example, between two functionally specialized regions of the brain) is significantly reduced (Watts and Strogatz 1998). Thus, with only a small number of long-range connections, various regions of the brain are brought very close together in a metabolically efficient manner by being organized in a small-world network fashion. It is interesting to note, as mentioned above, that about 2%–3% of all cortical neurons in the frontal lobe send projections to the contralateral hemisphere.

## REFERENCES


Andersen, P., R. G. Morris, D. G. Amaral, T. Bliss, and O'Keefe. 2007. *The hippocampus book*. New York: Oxford University Press.

Boxer, A. L. 2007. Principles of motor control by the frontal lobes as revealed by the study of voluntary eye movements. In *The human frontal lobes*. B. L. Miller and J. L. Cummings. New York: Guilford Press.

Broca, P. 1861. Remarques sur le siège de la faculté du language articulé, suives d'une observation d'aphémie (perte del la parole). *Bull. Soc. Anat.* 280:834–843.

Brodmann, K. 1909. *Vergleichenden Lokalisationslehre der Grosshirnrinde*. Leipzeig: Johann Ambrosius Barth Verlag.

Buzáski, G. 2006. *Rhythms of the brain*. New York: Oxford University Press.

Carpenter, M. B. 1991. *Core text of neuroanatomy*. Baltimore: Williams & Wilkins.

Chow, T. W. and J. L. Cummings. 2007. Frontal–subcortical circuits. *The human frontal lobes*. B. L. Miller and J. L. Cummings. New York: Guilford Press.

Craig, A. D. 2009. How do you feel—now? The anterior insula and human awareness. *Nat. Rev. Neurosci.* 10(1):59–70.

Douglas, R., H. Markram, and K. Martin. 2004. Neocortex. In *The synaptic organization of the brain*. G. M. Sheppard, 719. Oxford: Oxford University Press.

Dronkers, N. F. 1996. A new brain region for coordinating speech articulation. *Nature* 384(6605):159–161.

Duvernoy, H. M. 2005. *The human hippocampus: Functional anatomy, vascularization, and serial sections with MRI*. New York: Springer-Verlag.

Ebersole, J. S. 2003. Cortical generators and EEG voltage fields. *Current practice of clinical electroencephalography*. J. S. Ebersole and T. A. Pedley. Philadelphia: Lippincott, Williams & Wilkins.

Ebersole, J. S. and T. A. Pedley. 2003. *Current practice of clinical electroencephalography*. Philadelphia: Lippincott, Williams & Wilkins.

Engel, J. J. 1993. *Surgical treatments of the epilepsies*. New York: Raven Press.

Ferrier, D. 1876. *The functions of the brain*. London: Smith, Elder.

Fristsch, G., and E. Hitzig. 1870. Ueber die elektrische Erregbarkeit des Grosshirns. *Arch. Anat. Physiol. Wiss. Med.* 300–332.

Geschwind, D. H., and M. Iacoboni. 2007. Structural and functional asymmetries of the human frontal lobes. *The human frontal lobes*. B. L. Miller and J. L. Cummings. New York: Guilford Press.

Goddard, G. V., D. C. McIntyre, and C. K. Leech. 1969. A permanent change in brain function resulting from daily electrical stimulation. *Exp. Neurol.* 25(3):295–330.

Harris, A. B., and J. S. Lockard. 1981. Absence of seizures or mirror foci in experimental epilepsy after excision of alumina and astrogliotic scar. *Epilepsia* 22(1):107–122.

Howe, K. L., D. Dimitri, C. Heyn, T.-R. Kiehl, D. Mikulis, and T. Valiante. 2010. Histologically confirmed hippocampal structural features revealed by 3T MR imaging: Potential to increase diagnostic specificity of mesial temporal sclerosis. *Am. J. Neuroradiol.* (epub ahead of print June 10, 2010).

Kim, U., M. V. Sanchez-Vives, and D. A. McCormick. 1997. Functional dynamics of GABAergic inhibition in the thalamus. *Science* 278(5335):130–134.

Kuffler, S. W., J. G. Nicholls, and A. R. Martin. 1984. *From neuron to brain*, 2nd ed. Sunderland, MA: Sinaur Associates.

Lamantia, A. S., and P. Rakic. 1990. Cytological and quantitative characteristics of four cerebral commissures in the rhesus monkey. *J. Comp. Neurol.* 291(4):520–537.

Llinas, R., U. Ribary, D. Contreras, and C. Pedroarena. 1998. The neuronal basis for consciousness. *Philos. Trans. R. Soc. Lond. B. Biol. Sci.* 353(1377):1841–1849.

McIntosh, A. M., S. J. Wilson, and S. F. Berkovic. 2001. Seizure outcome after temporal lobectomy: Current research practice and findings. *Epilepsia* 42(10):1288–1307.

Miller, B. L., and J. L. Cummings. 2007. *The human frontal lobes*. New York: Guilford Press.

Moscovitch, M., R. S. Rosenbaum, A. Gilboa, D. R. Addis, R. Westmacott, C. Grady, M. P. McAndrews, B. Levine, S. Black, G. Winocur, and L. Nadel. 2005. Functional neuroanatomy of remote episodic, semantic and spatial memory: A unified account based on multiple trace theory. *J. Anat.* 207(1):35–66.

Nieuwenhuys, R., J. Voogd, and C. van Huijzen. 1988. *The human central nervous system: A synopsis and atlas*. New York: Springer-Verlag.

Ojemann, G., J. Ojemann, E. Lettich, and M. Berger. 1989. Cortical language localization in left, dominant hemisphere. An electrical stimulation mapping investigation in 117 patients. *J. Neurosurg.* 71(3):316–326.

Penfield, W., and T. Rasmussen. 1950. *The cerebral cortex of man*. New York: Macmillan.

Sheppard, G. M. 2004. *The synaptic organization of the brain*. Oxford: Oxford University Press.

Steriade, M., and M. Deschenes. 1984. The thalamus as a neuronal oscillator. *Brain. Res.* 320(1):1–63.

Tai, P., S. Poochikian-Sarkissian, D. Andrade, T. Valiante, M. del Campo, and R. Wennberg. 2010. Postictal wandering is common after temporal lobe seizures. *Neurology* 74(11):932–933.

Valiante, T. A. 2009. Selective amygdalo-hippocampectomy. In *Textbook of stereotactic and functional neurosurgery*. A. Lozano, P. L. Gildenberg, and R. Tasker. Heidelberg, 2677–2714. New York: Springer-Verlag.

Watts, D. J., and S. H. Strogatz. 1998. Collective dynamics of 'small-world' networks. *Nature* 393(6684): 440–442.

# 2 Introduction to EEG for Nonepileptologists Working in Seizure Prediction and Dynamics

*Richard Wennberg*

**CONTENTS**

2.1 Introduction ..... 23
2.2 Generation of the Potentials Recorded with EEG ..... 23
2.3 Types of Potentials Recorded with EEG ..... 25
2.4 EEG Recording Conventions ..... 26
2.5 EEG Examples ..... 28
2.6 Artifacts and Reference Electrodes ..... 28
2.7 Limitations of Scalp EEG Recording ..... 35
2.8 Intracranial EEG ..... 37
References ..... 38

## 2.1 INTRODUCTION

The aim of this chapter is to provide a brief introduction to electroencephalography (EEG), specifically oriented toward nonclinicians working in the fields of seizure prediction and dynamical analysis. As such, only very limited attention will be given to the use and clinical interpretation of EEG in the diagnosis and treatment of the various epilepsy syndromes. For those interested in reading more about the clinical applications of EEG in epilepsy, the textbooks edited by Daly and Pedley (1990) and by Niedermeyer and Lopes da Silva (1993) are highly recommended. Additional information pertaining to the neurophysiology of electrogenesis and other aspects of EEG recording and interpretation can be found in the material used for the Fourth International Workshop on Seizure Prediction (IWSP4) didactic lecture that served as the basis for this book chapter (available at www.iwsp4.org/DidacticForNonMDs/Wennberg_Richard_EEG_for_NonEpileptologists.ppt). Perhaps the single most useful reference paper that could be recommended for this audience would be that of Gloor (1985) on neuronal generators, localization, and volume conductor theory in EEG.

## 2.2 GENERATION OF THE POTENTIALS RECORDED WITH EEG

The signal recorded with EEG is a representation of voltage fluctuations in space and time, the electrical potentials arising from summated excitatory and inhibitory postsynaptic potentials that are generated mainly by cortical pyramidal cells (Gloor 1985; Pedley and Traub 1990; Lopes da Silva and Van Rotterdam 1993; Speckmann and Elger 1993). “Synchronous” neural activity involving at

least 6 cm$^2$ of cortex is considered necessary for detection with scalp EEG (Cooper et al. 1965), and pathological epileptiform potentials typically involve larger cortical areas extending over at least 10–20 cm$^2$ (Tao et al. 2005).

It is the parallel arrangement of pyramidal neurons in the cortical mantle, with their apical dendrites extending to the most superficial cortical layers, that gives rise to the effective "cortical dipole layer" that dominates the signal recorded with EEG (Gloor 1985). Sufficiently summated excitatory postsynaptic potentials (EPSPs) at the apical dendrites will cause inward current flow and a superficial cortical "sink"—if the area of synchronous excitation is large enough, the extracellular negative field resulting from the inward apical current flow will be detected by scalp EEG and depicted as an upward waveform (Pedley and Traub 1990; Speckmann and Elger 1993). The "source" corresponding to the simultaneous outward current flow will be situated deeper, near the pyramidal cell body layer, and thus not detected by the surface EEG recording. The superficial versus deep location of sources and sinks in the cortical dipole layer will reflect the predominant direction of current flow in the cortical dipole layer at a given point in time. Superficial sinks can arise from either summated apical EPSPs or summated deep-cell body layer inhibitory postsynaptic potentials (IPSPs), whereas superficial sources can result from either summated apical IPSPs or deep EPSPs (Pedley and Traub

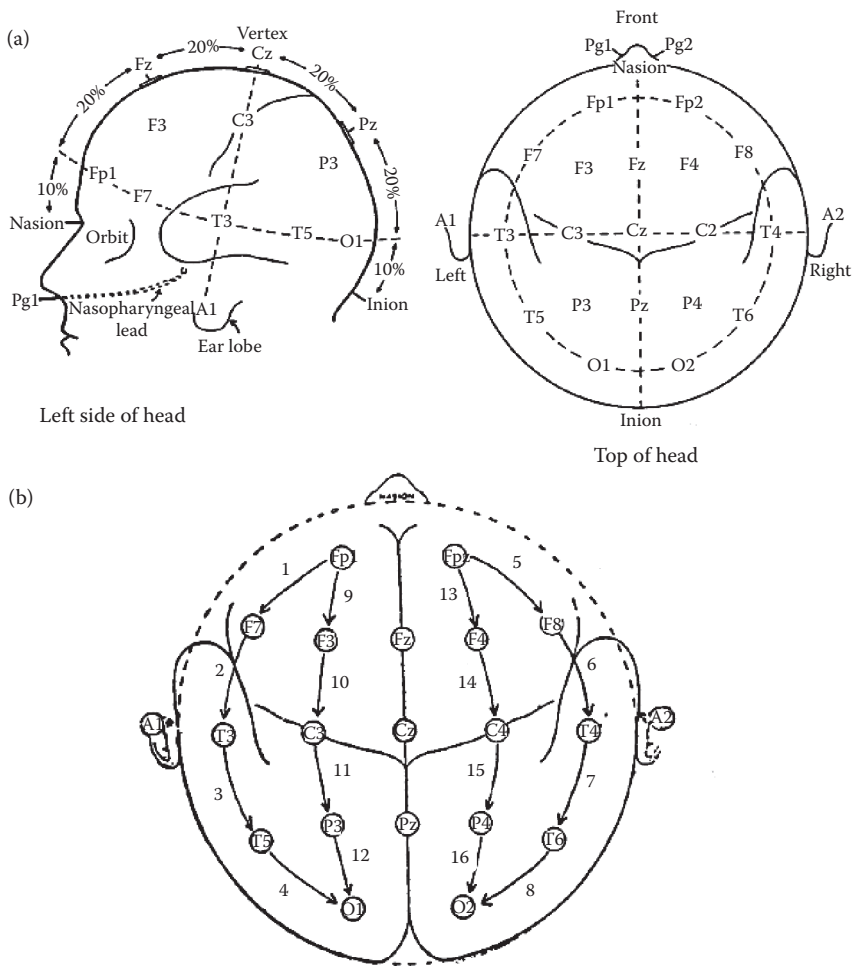


**FIGURE 2.1** (a) International 10-20 system for scalp EEG electrode placement. (b) Sixteen-channel array of the anterior–posterior longitudinal ("double banana") montage.

1990; Speckmann and Elger 1993). It is the extracellular polarity of the superficial cortical field that is recorded with EEG, negative for a superficial sink, positive for a superficial source (Gloor 1985; Pedley and Traub 1990; Lopes da Silva and Van Rotterdam 1993; Speckmann and Elger 1993).

## 2.3 TYPES OF POTENTIALS RECORDED WITH EEG

In a broad sense, the potentials recorded with EEG can be classified into two types of phenomena: oscillations and transients. Oscillatory activity recorded with EEG is generated in the cortex and dependent to varying degrees on thalamocortical reciprocity (Steriade 1993). The recorded oscillations can be normal (alpha, beta, gamma, and mu rhythms, sleep spindles, and delta activity in sleep) or abnormal (seizures, burst-suppression). Oscillatory activity and, especially, seizure activity is, of course, the type of EEG signal of interest to this audience.

EEG sharp transients are usually of less interest for the purposes of seizure prediction and dynamical analyses (and can sometimes confound these analyses), although they are important for diagnostic purposes. Normal transients include a variety of sleep potentials (vertex waves, K-complexes, positive occipital sharp transients of sleep, benign epileptiform transients of sleep) as well as a number of noncerebral electrical potentials that are detected with EEG—eye blinks, cardiac impulses (EKG), and muscle activity (EMG). Abnormal EEG sharp transients often form the basis for the diagnosis of epilepsy and are referred to as interictal epileptiform potentials, identifiable by their particular morphological characteristics, which may be in the form of spikes, polyspikes, spike and wave

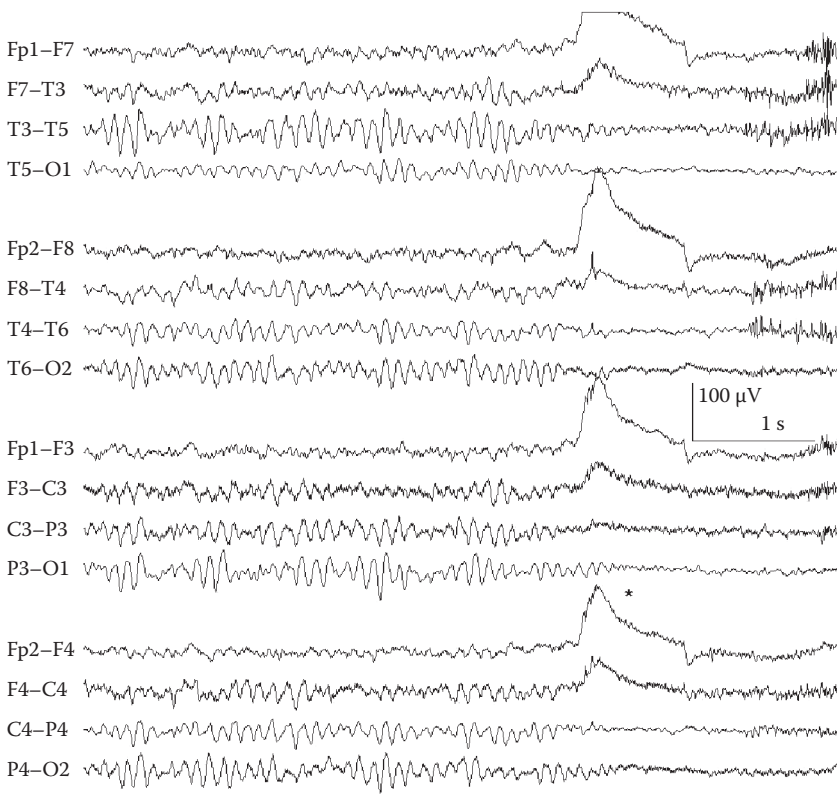


**FIGURE 2.2** Subject is awake and resting. Normal posterior alpha rhythm disappears with eye opening (*). High-frequency activity at the end of the figure after eye opening is muscle artifact. Anterior–posterior bipolar montage. LFF 0.5 Hz, HFF 70 Hz in this and all other figures.

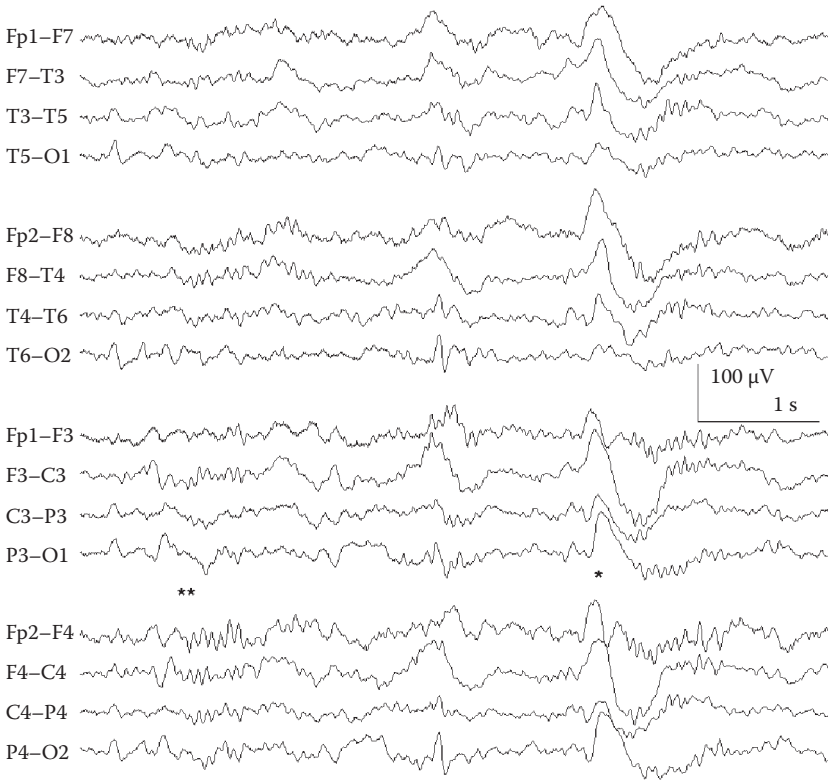


**FIGURE 2.3** Stage II sleep. K-complex (*); sleep spindles (**). Anterior–posterior bipolar montage.

complexes, sharp waves, and sharp and slow wave discharges. Certain other nonepileptiform EEG transients, such as periodic complexes (lateralized and generalized) and triphasic waves can be indicators of various encephalopathies (Daly and Pedley 1990; Niedermeyer and Lopes da Silva 1993).

## 2.4 EEG RECORDING CONVENTIONS

There is a long-established convention for head measurement and EEG scalp electrode placement and labelling known as the international 10-20 system (Daly and Pedley 1990; Niedermeyer and Lopes da Silva 1993), with electrodes on the left assigned odd numbers, electrodes on the right assigned even numbers, and midline electrodes given the suffix "Z." Electrodes over frontal regions are denoted with the prefix "F," with "C," "T," "P," and "O" indicating electrode placement over central, temporal, parietal, and occipital regions, respectively (Figure 2.1).

EEG recordings are displayed for review and interpretation using different configurations of electrode combinations organized into "channels," with each channel containing two electrode inputs that are arranged into either *bipolar* or *referential* montages. All recorded EEG signals are a measure of the voltage differences at one electrode site relative to another electrode. By convention, polarity in clinical EEG is depicted as "negative up." Specifically, if the field potential recorded at the first electrode (input) of a channel is relatively more negative than the potential recorded at the same channel's second electrode input, then the difference is reflected as an upward waveform, and vice versa.

Bipolar montages are typically arranged in straight line chains of electrodes, where the second input of the first channel becomes the first input of the second channel, and so on, allowing for

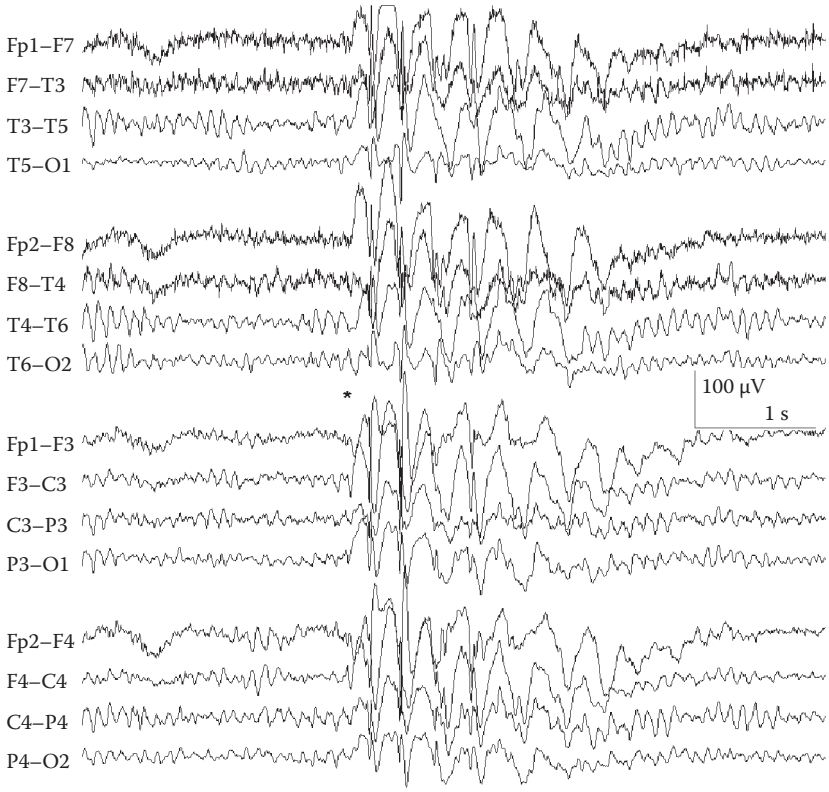


**FIGURE 2.4** A burst of generalized 3-Hz spike and wave activity (*). Primary generalized epilepsy. Anterior–posterior bipolar montage.

localization of electrical field maxima and minima by so-called "phase reversal." Note that "phase" is used here in a different sense from that used in dynamical studies; a more accurate term would be "polarity reversal." Referential montages are actually also bipolar arrangements, except that the second input to each channel (referred to as the "reference electrode") is more distant in space from the first electrode position. It is usually situated somewhere on the scalp, occasionally on the mastoids or ear lobes or, less commonly, over the cervical spine or nose. In referential montages, electrical fields are localized by identification of amplitude maxima and minima at the recording electrode (first input) sites. These types of referential montages are sometimes also referred to as *monopolar* montages, which is not a truly accurate designation but is understood clinically. An ideal monopolar reference electrode would be electrically neutral to cerebral activity and uncontaminated by electrical artifact. Unfortunately, no such ideal electrode exists and all usable reference electrode positions have drawbacks. The reference electrode input can also be constructed from an average of some or all of the signals recorded from the other scalp electrodes. Examples including the common average reference, used extensively for EEG source localization and modelling of sharp transients, and the surface Laplacian, a more sophisticated local average reference that may be useful for decreasing the contribution of volume conducted distant electrical fields to the signal recorded from the electrode site of interest, the first input to the channel (Nunez et al. 1997).

Clinically, one of the most commonly used screening montages for scalp EEG review is the so-called anterior–posterior longitudinal bipolar (or "double banana") montage, which is shown at the bottom of Figure 2.1 and used to depict the scalp EEG examples in Figures 2.2 through 2.6.

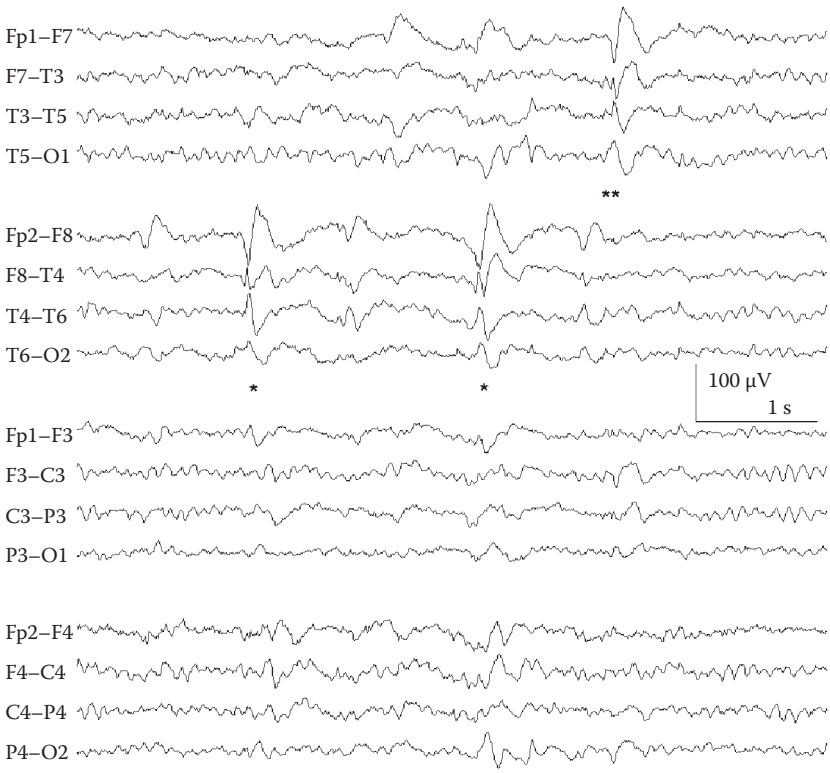


**FIGURE 2.5** Bilateral temporal lobe (focal, partial) interictal epileptiform activity. Independent sharp and slow wave complexes over right (*) and left (**) anterior–mid-temporal regions. Temporal lobe epilepsy. Anterior–posterior bipolar montage.

## 2.5 EEG EXAMPLES

Figure 2.2 shows an example of the EEG of normal wakefulness. This can be contrasted with the EEG of normal (stage 2) sleep that is shown in Figure 2.3. The classical 3-Hz spike and wave activity of primary generalized epilepsy is shown in Figure 2.4. Figure 2.5 shows temporal lobe interictal epileptiform discharges (spikes) such as may be seen in temporal lobe epilepsy. Figure 2.6 shows part of an ongoing right temporal lobe seizure.

## 2.6 ARTIFACTS AND REFERENCE ELECTRODES

The EEG time series data that is available to nonepileptologists for analysis is typically first selected by clinical electroencephalographers after transformation of the data to some type of manipulable format (e.g., a large .txt file). Detailed consideration may not always be given to the issue of possible artifacts in the recording, and the issue of reference electrode choice is frequently not addressed. Indeed, at times mathematicians and physicists working with EEG data may not have been made aware by their clinical colleagues of the reference electrode used for a particular segment of data.

Although the issues related to artifacts and reference electrode contamination form an integral part of routine clinical EEG interpretation, they are really no less important for nonclinicians using EEG signal analysis to study seizure prediction and dynamics.

A good example of the importance of understanding artifacts is the recent demonstration that scalp EEG studies of beta and gamma oscillations in cognition over the past many years would

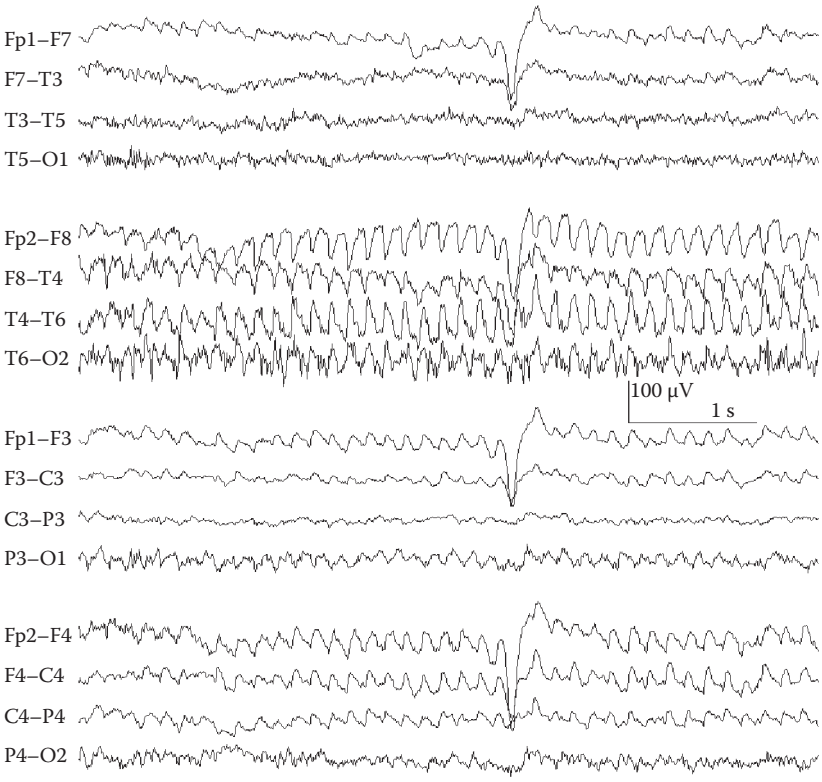


**FIGURE 2.6** Ictal EEG showing focal rhythmic seizure pattern localized to right temporal region ("equipotentiality" at F8–T4). Temporal lobe epilepsy. Anterior–posterior bipolar montage.

appear to have been analyzing mainly muscle artifact (Whitham et al. 2007, 2008), a finding not entirely surprising to some clinical electroencephalographers but one that throws into question decades of published research.

The effects of reference electrodes on measures of EEG correlation, coherency, or synchronization have been discussed in the past (Nunez et al. 1997; Zaveri et al. 2000) but are nevertheless often overlooked in the signal analysis literature (Guevara et al. 2005). The choice of reference electrode can have greater or lesser effects on classical measures of synchronization such as correlation or coherency analyses (Nunez et al. 1997; Zaveri et al. 2000). Modern techniques such as phase synchronization analysis are also affected by the choice of reference electrode, with the resulting amplitude variations influencing the synchrony measured and disrupting the intended benefit of the technique, which is designed to remove the effects of signal amplitude from the synchrony ("phase locking") measured (Guevara et al. 2005).

For a visual presentation of the effects of reference electrode choice (and referential vs. bipolar arrays), a single 10-second epoch of EEG is presented in Figure 2.7a through f in six different montages, including one bipolar montage and five different referential montages. A careful analysis of the different waveforms—especially the very evident, labelled transient physiological artifacts—with respect to their amplitude and polarity changes across the different montages will provide the interested reader with an excellent opportunity to begin to understand the process of visual EEG interpretation. Even a cursory comparison of the six different depictions of the same 10 s of EEG will make clearly evident the important effects of reference electrode choices. In Figure 2.8, graphic representations of 300 ms of EEG data points—selected from the same 10-second epoch, using the six different recording arrays shown in Figure 2.7 (one bipolar and five referential), the EEG